

ISAPS® NEWS

OFFICIAL NEWS OF THE INTERNATIONAL
SOCIETY OF AESTHETIC PLASTIC SURGERY

Volume 15 | Number 1



INSIDE ■

Breast Reduction:
How I Do It

Meet Our
New Leadership

Spotlight on Global
Accreditation

BOARD OF DIRECTORS

PRESIDENT

Nazim Cerkes, MD, PhD
Istanbul, TURKEY
ncerkes@hotmail.com

PRESIDENT-ELECT

Lina Triana, MD
Cali, COLOMBIA
linatriana@drlinatriana.com

SECRETARY

Arturo Ramirez-Montañana, MD
Monterrey, MEXICO
docarturo@gmail.com

TREASURER

Tim Papadopoulos, MD
Sydney, AUSTRALIA
drtim@drtim.com.au

MEMBERSHIP CHAIR

Vakis Kontoes, MD, PhD
Athens, GREECE
vakiskont@gmail.com

MEMBER-AT-LARGE

Fabian Cortiñas, MD
Buenos Aires, ARGENTINA
fabiancortinas@gmail.com

MEMBER-AT-LARGE

Kai-Uwe Schlaudraff, MD, FEBOPRAS
Geneva, SWITZERLAND
schlaudraff@concept-clinic.ch

MEMBER-AT-LARGE

Ivar van Heijningen, MD
Knokke-Heist, BELGIUM
i.vanheijningen@duinbergen-clinic.be

MEMBER-AT-LARGE

Niveo Steffen, MD
Sao Leopoldo, BRAZIL
clinsteffen@gmail.com.br

PAST PRESIDENT

Dirk Richter, MD
Wesseling, GERMANY
president@isaps.org

NATIONAL SECRETARIES CHAIR

Michel Rouif, MD
Tours, FRANCE
michel.rouif@wanadoo.fr

PARLIAMENTARIAN

Sanguan Kunaporn, MD
Phuket, THAILAND
Sanguan.Ku@phuketpsi.com

EDUCATION COUNCIL CHAIR

Ozan Sozer, MD
Bitte El Paso, TX, UNITED STATES
doctor@elpasoplasticsurgery.com

EDUCATION COUNCIL VICE CHAIR

Francisco Bravo, MD
Madrid, SPAIN
fgbravo@clinicagomezbravo.com

TRUSTEE

Renato Saltz, MD, FACS
Salt Lake City, UT, UNITED STATES
rsaltz@saltzplasticsurgery.com

EXECUTIVE DIRECTOR

Sarah Johnson
UNITED KINGDOM
isaps@isaps.org

no1
VOLUME 15

CONTENTS

Message from the Editor	3
Message from the <i>ISAPS News</i> Co-Chair	5
Message from the ISAPS President	7
Message from the Education Council Chair	9
Global Alliance	12
Global Accreditation	13
Humanitarian Report	14
National Secretaries Chair Report	16
Journal Update	18
Guest Article from ISAPS Global Sponsor	19
In Memoriam	20
History	21
Breast Reduction: How I Do It	25
Patient Safety	39
New Members	44
Meetings Calendar	47

NOTICE OF NEW ADDRESS

ISAPS has moved administration to virtual offices.

Please make a note of our new address:

International Society of Aesthetic Plastic Surgery (ISAPS)

10 Benning Street, Suite 160 #264

West Lebanon, New Hampshire 03784-3402 USA

The telephone number remains the same:

+1-603-643-2325

MESSAGE FROM

the Editor-in-Chief



ARTURO RAMIREZ MONTAÑANA - MEXICO
Editor-in-Chief, *ISAPS News*

Dear Colleagues,

Welcome to the first issue of volume 15 of *ISAPS News*. I hope that this issue finds you, your families, and your staff in good health.

As some of you already know, we have a brand-new editorial team working on *ISAPS News*. Our goal is to introduce a new philosophy to the newsletter, making it more like a magazine, by including cultural aspects, personal interests of members, and lifestyle sections.

This quarter, the topic is **Breast Reduction: How I Do It**, and we have received a great variety of articles, each of which cover a different aspect of this technically challenging procedure. We have presented a truly global perspective on this topic, as well as standout articles. One of these is by Dr. Elizabeth Hall-Findlay (Canada) and Dr. Gustavo Jimenez (Mexico), who deliver a highly practical article based on their extensive experience.

Our next issue will look at **Facial Fat Transfer: How I Do It** and we would love to see articles covering the full range of facial techniques, including implants, fat grafting and revision. If you are interested in submitting an article on this topic, please send your submission to isapsnews@isaps.org by April 15.

APPLYING DARWIN TO CORONAVIRUS: KEEPING OUR PRACTICES FIT

"Few thinkers have had quite the same impact as Charles Darwin. His theory of evolution was so powerful and compelling that it became the new orthodoxy, affecting how we think about many aspects of our lives. Not least of these influences has been on the way we do business."
Morgan Witzel

We continue to struggle with the COVID-19 pandemic worldwide and will likely continue to feel its effects. In this new age, many of the old rules of business no longer apply, and traditional approaches to attracting customers do not work. There has been a fundamental shift in how organizations operate, and we must be innovative and create new and exciting methods for getting new patients.

SURVIVAL OF THE FITTEST

"It is not the strongest species that survive, nor the most intelligent, but the ones most responsive to change."

Leon C. Megginson

What does 'survival of the fittest' mean in the COVID-19 pandemic? Businesses and industries are approaching this differently and achieving various results, but as we are seeing first-hand, businesses must evolve to thrive and survive. A business must have a critical mix of diagnostic and matchmaking skills. They must be able to read their internal capabilities and the wants and needs of the external marketplace, and then align these two. Even now, during this crisis, the possibilities for change are out there, and we must take advantage of them. Remember, those who adapt the fastest prosper!

INNOVATION IS THE BEST WAY OUT OF A CRISIS

In the recent past, we have seen companies who failed to adapt. One example of this is Blockbuster, the internationally known video rental service. The video rental business was hugely profitable from day one, but Blockbuster faced their biggest challenge to date. You see, the environment was changing and so were customers' needs. They no longer wanted to go

to the store and rent a tape: instead, they wanted to watch TV shows and movies on demand from the comfort of their own homes.

Blockbuster had a choice: adapt or fail. They could have moved away from physical DVD rentals to digital and mail-order video delivery. However, their attempts to change were too little, too late, and the company began experiencing huge losses. Some figures suggest that by the end of 2009, the company's debt had climbed to as high as \$856 million. Netflix had come along in 1999 and done exactly what Blockbuster had failed to do. After starting out as a mail delivery video service, Netflix continued to adapt and eventually moved entirely to the digital domain, where it is now the go-to provider of home entertainment in the form of watching your favorite shows on demand.

This example clearly illustrates how Digital Darwinism works - if your business fails to adapt to the new trends, you will be on a path to failure.

APPLYING DARWIN TO OUR PRACTICE

Our field of business is no different from the rest and follows the same rule - adapt and thrive, or fail to do so and become obsolete. If we want to survive with a healthy practice, we must do the following:

- Telemedicine - we need to adapt to modern telemedicine tools, such as virtual consultations and video conferencing platforms
- Nonsurgical > surgical - surgical procedures are less common at the moment due to restrictions on nonessential procedures and the economic impact of COVID-19 on patients, so we need to focus on the procedures we can offer patients

- Spend wisely - during these times, we need to make sure we spend money exclusively when necessary, to keep money in our pockets until things are back to normal
- Go virtual - connect with your patients, with ISAPS, and with events virtually, and don't forego further education just because it's not possible in person

APPLYING DARWIN TO ISAPS

As a society, we have already implemented many techniques designed to keep us constantly evolving and adapting. We regularly elect a new Board of Directors to ensure that we get fresh ideas and new responses to issues we may face. And for the first time ever, we have implemented an electronic voting system, allowing for members to vote without having to meet in-person, which is currently not possible.

In this new era of travel bans and event restrictions, we have continued our focus on aesthetic education and not only replaced in person events with virtual ones, but also created entirely new digital events for our members around the world to take part in. Alongside our monthly Master Class webinar series, ISAPS has started a brand-new Residents Series and has planned the first-of-its-kind 48-hour worldwide aesthetic event, ISAPS WORLD, for this month.

Darwin's theory of survival of the fittest is still relevant today. For ourselves and for our practice, our philosophy must always be to adapt and evolve to survive. With that in mind, I am excited to take on *ISAPS News* along with my new editorial team and help it evolve and grow.

Be safe and be well.



Arturo Ramirez Montañana, MD, Editor-in-Chief

MESSAGE FROM

the *ISAPS News* Co-Chair



FABIAN CORTIÑAS - ARGENTINA
Co-Chair, *ISAPS News*

INTRODUCING THE ‘NEW’SLETTER

Dear Colleagues and Friends,

Anyone who has the chance to experience our upcoming virtual event, **ISAPS WORLD**, on March 27-28 is bound to be attracted to the charming scenario that is ISAPS: a multicultural society that is made up of over 4,000 members and includes more than 100 countries and over a dozen languages, comprises almost all time zones, and shares one common passion that links us all: our devotion to Aesthetics.

The place we all meet every three months is our newsletter, *ISAPS News*; here we share what we do, our wins and losses, the latest plastic surgery developments, and anything related to the evolution of our society.

WE ARE STANDING ON THE SHOULDERS OF GIANTS

Our predecessors have done a great job building up the newsletter. As part of the new editorial team, we are looking forward to bringing our own perspective to the newsletter and to evolving its DNA a little bit more. I am excited to introduce some of the new sections that will be incorporated in future issues of *ISAPS News*.

HOW I DO IT

Through the newsletter, our members have shared their “Global Perspectives” on aesthetic procedures. This has been an outstanding experience that has shown how the same topic can be treated differently throughout the world. Moving forward,

these “Global Perspectives” on a topic will transition into “How I Do It.” As an international society, our members’ unique take on a procedure already provides a global perspective. With “How I Do It,” we hope to open the floor to anyone who wants to teach their personal technique. We invite you to submit more informal articles highlighting your personal technique for the selected topic in a collegial atmosphere. “How I Do It” articles will focus on short descriptions of techniques using pictures and may even include a link to a video.

OUR DNA

Future issues of *ISAPS News* will include new sections designed to showcase our multicultural background. By adding these new categories, we hope to make our newsletter attractive not only to us but also to the public, to future patients, and to our future members.

ISAPS Gourmet will feature short articles from members with quick recipes and descriptions about local food. This section can also include restaurant recommendations in your area and tips to improve our eating experience around the world.

ISAPS Culture will give our members the opportunity to share the iconic cultural aspects of their countries, highlighting local art exhibitions, renowned museums, and regional history from the individual viewpoints of our members.

ISAPS Health will include members' takes on their favorite sports, sports recommendations, as well as anything related to wellness and fitness, from meditation to dietary guidelines. This section should be informative for both our colleagues and our patients.

ISAPS Travel will provide travelers with a place to offer their personal travel tips to readers. Here, members can describe the hidden secret gems in their countries and offer local tips for their region.

The **Residents Corner** for ISAPS residents is going to become more comprehensive and will serve as a place for residents to share their stories, talk about their dreams and latest projects, highlight certain programs and events, and call for cooperative work.

ISAPS has more than 4,500 members in 107 countries and we each have a unique perspective to share with each other.

We want this newsletter to be the place where we can all meet and share our unique experiences and present attractive information about our countries, ourselves, and of course, our practice.

Whether you are a resident, a mentor, a new member, or a long-time member of the ISAPS family, we invite you to participate on this journey as we evolve the newsletter and help it grow. If you are interested in submitting an article to *ISAPS News*, please contact isapsnews@isaps.org for details.

Thank you for your support - we are excited to get started on this new adventure with you!

Best regards,



Fabian Cortiñas, MD, *ISAPS News* Co-Chair



MESSAGE FROM

the ISAPS President

Dear ISAPS members, friends, and colleagues,

I am hopeful that 2021 will be a better year for all of us and I am looking forward to seeing you all again in person as soon as it is safe to do so. In the meantime, we can connect digitally at virtual events like **ISAPS WORLD**, which I am excited to be a part of in just two weeks. It is important to remember that we are all united as part of the ISAPS family, wherever we each may be.

Here at ISAPS, we have been busy in the first quarter of 2021 preparing new and exciting things to come for you!

ISAPS NEWS

I am pleased to usher in a new editorial team for our quarterly newsletter, *ISAPS News*. After many years of dedication and great work, Managing Editor Catherine Foss and Editor-in-Chief Dr. Nina Naidu (USA) have handed over the newsletter to a new team. Drs. Arturo Ramirez-Montañana (Mexico) and Fabian Cortiñas (Argentina) have taken the reins as Editor-in-Chief and *ISAPS News* Co-Chair, respectively. They are excited to bring their own perspectives and new ideas to the newsletter and I look forward to seeing how the newsletter evolves. A big thank you to Catherine Foss and Nina Naidu for their hard work in the past.

ISAPS WORLD

Our first non-stop virtual conference, **ISAPS WORLD**, will bring the entire world together in just two weeks on March 27-28. Over a 48-hour period, more than 400 speakers from the following regions will present the latest in aesthetic plastic surgery: Australia, New Zealand & Far East Asia; Middle East, Africa & South Asia; Europe; North America; and Latin America. I hope you will join us and participate in exciting parallel sessions, live symposia, and a virtual

exhibition, as well as enjoy the opportunity to network with colleagues and friends from all over the world!

ISAPS EXECUTIVE OFFICE

At the end of last year, Catherine Foss retired from her position as Executive Director, passing on the role to Sarah Johnson. In addition, we have added two new staff members: Richard Guy for Membership Management and Laura Lundy for Event Management. Richard is responsible for managing our growing group of members and supporting their needs, while Laura is helping create our educational Residents Program and further develop the ISAPS Fellowship Program. I am confident that our new executive team will work hard to bring ISAPS to an even higher level.

TEAM MEETINGS

During my term, ISAPS' leadership has been meeting regularly to plan events, discuss objectives, and strategize about ways to grow our leadership in aesthetic education and patient safety in this new era. The Board of Directors meets every two months while the Executive Committee meets monthly to make necessary decisions. I would like to thank my Board and the Executive Committee for their commitment to ISAPS and their enthusiasm.

In the past four months, I have had two productive meetings with our National Secretaries during which we talked about the communication between plastic surgeons and patients, strategies for membership growth, and how to further improve the quality of ISAPS education. We also organized a Strategic Planning Meeting with Global Alliance Partners, where I heard from our partner societies on topics like patient safety, global accreditation and universal

standards, and resident teaching. These meetings have been invaluable in helping us better understand members' expectations. Especially in these difficult times, we can be stronger together, and I look forward to working closely with my fellow Global Alliance Partners to strengthen these opportunities during my term.

ISAPS RESIDENTS PROGRAM

ISAPS is committed to the future generation of plastic surgeons. At the beginning of the year, we launched a refreshed and enhanced Residents Program, specifically targeted to the needs of residents. Resident members will now have the chance to join our monthly virtual educational sessions and take part in new mentorship opportunities, and will continue to benefit from our existing Fellowship Program. We also launched a new Meet the Expert webinar series for ISAPS' residents, the first of which I participated in on January 30th. These Meet the Expert sessions will continue throughout the year with experts in various fields of aesthetic surgery.

ISAPS MEMBERSHIP

Despite the ongoing pandemic, membership renewal for 2021 was very high. I would like to thank our National Secretaries, who put in a great deal of effort to retain members in their countries, for their hard work. I would also like to express my gratitude to all our members who have decided to stay with us. ISAPS is your society and we will continue to strive to better serve you and grow our community with you.

Here's to a better year - happy reading!

Sincerely,



Nazim Cerkes, MD, PhD
ISAPS President, 2020-2022

MESSAGE FROM

the Education Council Chair



OZAN SOZER - UNITED STATES
Chairman, ISAPS Education Council

Dear ISAPS Members,

Happy New Year! 2020 was far from the special year we hoped for, but I am hopeful that 2021 will be an improvement. Despite the pandemic, I am pleased to announce that ISAPS' Education Council has been working hard to bring you the best aesthetic education in the world, even virtually. I would like to take this opportunity to focus on an event that has been created for this purpose and will take place on March 27 - 28: **ISAPS WORLD**.

In the new world of virtual education, we are all getting weary of the overabundance of webinars. However, ISAPS WORLD is not like any other virtual event. Rather, it is a collaborative effort designed to bring surgeons from all over the world together in a nonstop 48-hour program during which the sun will not set over ISAPS.

The last time the whole world got together was the 2018 ISAPS World Congress in Miami, which I believe was one of the best aesthetic meetings we had ever organized. However, despite the meeting's success, it wasn't perfect: the registration fee was over \$1,000, participants had to take time off of work and pay for travel and lodging, and only one conference could be attended at a time.

Although we all miss the live events of the past, ISAPS WORLD is the only event where you can witness the world coming together in the name of ISAPS, all from the comfort of your living room. You will be able to ask questions to talented surgeons

from all parts of the world, visit the virtual exhibition, and chat with your friends from far away - even in your pajamas! Moreover, you will be able to hear some of these programs delivered in their native languages while still being able to understand everything through the provided subtitles. Once the event has ended, all exclusive content will be available to revisit on demand for one month.

All of this and more is available to our members for a small fee beginning at only \$100. I sincerely believe that this will be the best \$100 you will spend this year, and I hope you will all join us in a couple of weeks.

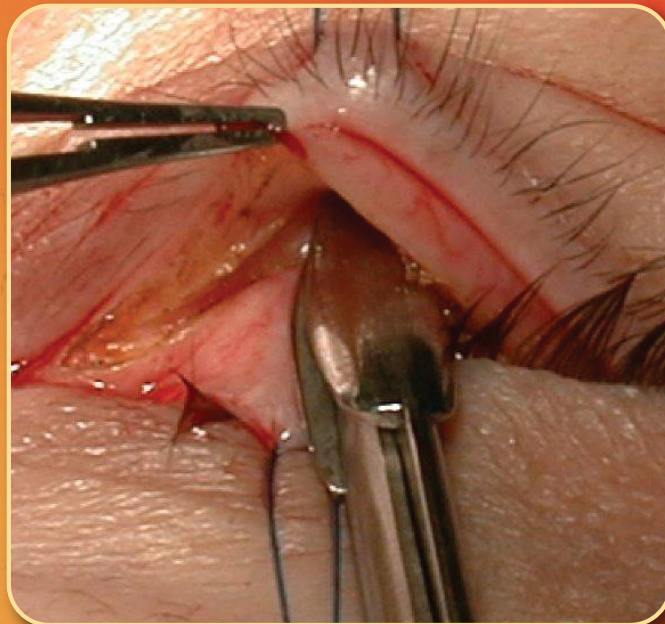
Alongside ISAPS WORLD and our monthly Master Class webinars, we have several more events planned for you this year. ISAPS Business School will be held on Saturday, April 17, a two-part Regenerative Medicine Meeting will take place in May and July, and ISAPS Hair Transplantation Course will take place on May 8 - 9. Of course, we are still hopeful that we will be able to organize some hybrid events during the second part of 2021.

Whether virtually or in person, I look forward to seeing all of you in the near future.

A handwritten signature in black ink, appearing to read 'Ozan Sozer', written in a cursive style.

Sincerely,
Ozan Sozer, MD

Trepsat Facial Flap Dissector Scissors



Dissecting the lower eyelids.



ASIM121626



ASIM121426



ASIM121526

assi® 

ACCURATE SURGICAL & SCIENTIFIC INSTRUMENTS®

For diamond perfect performance™

accurate surgical & scientific instruments corporation

300 Shames Drive, Westbury, NY 11590

800.645.3569 516.333.2570 fax: 516.997.4948 west coast: 800.255.9378

Info: assi@accuratesurgical.com • Orders: orders@accuratesurgical.com

www.accuratesurgical.com

Designed by Surgeons, for Surgeons in collaboration with



REVISION INSURANCE

Reimbursement to surgeons for the cost of correcting a diagnosed condition

**NO FAULT
COVERAGE**

*for the two-years
post procedure*

**PEACE
OF MIND**

*with no additional
cost to the Surgeon
or Patient*

**FAST
REMEDY**

*with improved
customer experience*

**OVER
70**

*surgical &
non-surgical
procedures
covered*

CLAIMS

*handled by
industry
specialists*

Now available to Surgeons in the United States

For more information visit www.RevisionInsurance.com or call (800) 849-3031



ISAPS GLOBAL ALLIANCE PARTICIPATING SOCIETIES

1. **ALGERIA**
Algerian College of Plastic and Aesthetic Surgery (CACPRE)
2. **ARGENTINA**
Sociedad Argentina de Cirugía Plástica Estética y Reparadora (SACPER)
3. **AUSTRALIA**
Australasian Society of Aesthetic Plastic Surgeons (ASAPS)
4. **AUSTRIA**
Österreichische Gesellschaft für Plastische, Ästhetische und Rekonstruktive Chirurgie (ÖGPÄRC)
5. **AZERBAIJAN**
Society of Plastic Surgery Azerbaijan (SPSA)
6. **BANGLADESH**
Bangladesh Society of Aesthetic Plastic Surgeons (BSAPS)
7. **BELGIUM**
Royal Belgian Society for Plastic Surgery (RBSPS)
8. **BOLIVIA**
Sociedad Boliviana de Cirugía Plástica Estética y Reparadora (SBCPER)
9. **BRAZIL**
Sociedade Brasileira de Cirurgia Plástica (SBCP)
10. **BULGARIA**
Bulgarian Association of Plastic, Reconstructive and Aesthetic Surgery (BULAPRAS)
11. **CANADA**
Canadian Society for Aesthetic Plastic Surgery (CSAPS)
12. **CHILE**
Sociedad Chilena de Cirugía Plástica, Reconstructiva y Estética (SCCPRE)
13. **CHINA**
Chinese Society of Plastic Surgery (CSPS)
14. **COLOMBIA**
Sociedad Colombiana de Cirugía Plástica, Estética y Reconstructiva (SCCP)
15. **CYPRUS**
Cyprus Society of Plastic, Reconstructive and Aesthetic Surgery (CySPRAS)
16. **CZECH REPUBLIC**
Czech Society of Aesthetic Surgery (CSAS)
17. **CZECH REPUBLIC**
Czech Society of Plastic Surgery (CSPS)
18. **DENMARK**
Dansk Selskab for Kosmetisk Plastikkirurgi (DSKP)
19. **DOMINICAN REPUBLIC**
Sociedad Dominicana de Cirugía Plástica Reconstructiva y Estética (SODOCIPRE)
20. **EASAPS**
European Association of Societies of Aesthetic Plastic Surgery (EASAPS)
21. **ECUADOR**
Sociedad Ecuatoriana de Cirugía Plástica, Reconstructiva y Estética (SECPRE)
22. **EGYPT**
Egyptian Society of Plastic and Reconstructive Surgeons (ESPRS)
23. **ESAPS**
European Society of Aesthetic Plastic Surgery (ESAPS)
24. **ESPRAS**
European Society of Plastic, Reconstructive and Aesthetic Surgery (ESPRAS)
25. **FINLAND**
Suomen Esteettiset Plastikkirurgit ry. (SEP)
26. **FRANCE**
Société Française des Chirurgiens Esthétiques Plasticiens (SOFCEP)
27. **GEORGIA**
Georgian Society of Plastic Reconstructive and Aesthetic Surgery (GEOPRAS)
28. **GERMANY**
Deutsche Gesellschaft der Plastischen, Rekonstruktiven und Ästhetischen Chirurgen e.V. (DGPRÄC)
29. **GERMANY**
Vereinigung der Deutschen Aesthetisch Plastischen Chirurgen (VDAPC)
30. **GREECE**
Hellenic Society of Plastic, Reconstructive and Aesthetic Surgery (HESPRAS)
31. **GUATEMALA**
Asociación Guatemalteca de Cirugía Plástica Estética y Reconstructiva (AGCOPER)
32. **HUNGARY**
Hungarian Society for Plastic, Reconstructive and Aesthetic Surgery (HSPRAS)
33. **INDIA**
Indian Association of Aesthetic Plastic Surgeons (IAAPS)
34. **INDONESIA**
Indonesian Association of Plastic Reconstructive and Aesthetic Surgeons (InaPRAS)
35. **IRAN**
Iranian Society of Plastic and Aesthetic Surgeons (ISPAS)
36. **IRELAND**
Irish Association of Plastic Surgeons (IAPS)
37. **ISAPS**
International Society of Aesthetic Plastic Surgery (ISAPS)
38. **ITALY**
Associazione Italiana di Chirurgia Plastica Estetica (AICPE)
39. **ITALY**
Società Italiana di Chirurgia Plastica Ricostruttiva ed Estetica (SICPRE)
40. **JAPAN**
Japan Society of Aesthetic Plastic Surgery (JSAPS)
41. **JORDAN**
Jordanian Society for Plastic and Reconstructive Surgeons (JSPRS)
42. **KAZAKHSTAN**
Kazakhstan Society of Aesthetic and Plastic Surgery (NSAPS)
43. **KOREA**
Korean Society of Aesthetic Plastic Surgery (KSAPS)
44. **KUWAIT**
Kuwait Society of Plastic Surgeons (KSPS)
45. **LEBANON**
Lebanese Society of Plastic, Reconstructive, and Aesthetic Surgery (LSPRAS)
46. **MALAYSIA**
Malaysian Association of Plastic, Aesthetic and Craniomaxillofacial Surgeons (MAPACS)
47. **MEXICO**
Asociación Mexicana de Cirugía Plástica Estética y Reconstructiva (AMCOPER)
48. **MOROCCO**
Société Marocaine des Chirurgiens Esthétiques Plasticiens (SOMCEP)
49. **NETHERLANDS**
Nederlandse Vereniging voor Esthetische Plastische Chirurgie (NVEPC)
50. **NICARAGUA**
Asociación Nicaragüense de Cirugía Plástica (ANCP)
51. **NORWAY**
Norwegian Society of Aesthetic Plastic Surgery (NSAP)
52. **OMAN**
Omani Society of Plastic, Reconstructive and Aesthetic Surgery (OSPRAS)
53. **OSAPS**
Oriental Society of Aesthetic Plastic Surgery (OSAPS)
54. **PAKISTAN**
Pakistan Association of Plastic Surgeons (PAPS)
55. **PANAMA**
Asociación Panameña de Cirugía Plástica, Estética y Reconstructiva (APCOPER)
56. **PERU**
Sociedad Peruana de Cirugía Plástica (SPCP)
57. **PHILIPPINES**
Philippine Association of Plastic, Reconstructive and Aesthetic Surgeons (PAPRAS)
58. **POLAND**
Polish Society of Plastic, Reconstructive and Aesthetic Surgery (PSPRAS)
59. **PORTUGAL**
Sociedade Portuguesa de Cirurgia Plástica Reconstructiva e Estética (SPCPRE)
60. **ROMANIA**
Romanian Aesthetic Surgery Society (RASS)
61. **RUSSIA**
Northeastern Society of Plastic and Reconstructive Surgeons (NESPRS)
62. **RUSSIA**
Russian Society of Plastic, Reconstructive and Aesthetic Surgery (RSPRAS)
63. **SAUDI ARABIA**
Saudi Plastic Surgery Care Society (SPSCS)
64. **SERBIA**
Serbian Society of Aesthetic Plastic Surgeons (SRBSAPS)
65. **SERBIA**
Serbian Society of Plastic, Reconstructive, and Aesthetic Surgery (SRBPRAS)
66. **SINGAPORE**
Singapore Association of Plastic Surgeons (SAPS)
67. **SOUTH AFRICA**
Association of Plastic, Reconstructive and Aesthetic Surgeons of Southern Africa (APRASSA)
68. **SPAIN**
Asociación Española de Cirugía Estética Plástica (AECEP)
69. **SPAIN**
Sociedad Española de Cirugía Plástica Reparadora y Estética (SECPRE)
70. **SWEDEN**
Svensk Förening för Estetisk Plastikkirurgi (SFEF)
71. **SWITZERLAND**
Schweizerische Gesellschaft für Aesthetische Chirurgie (SGAC)
72. **SWITZERLAND**
Swiss Society of Plastic, Reconstructive and Aesthetic Surgery (SSPRAS)
73. **TAIWAN**
Taiwan Society of Aesthetic Plastic Surgery (TSAPS)
74. **TAIWAN**
Taiwan Society of Plastic Surgery (TSPS)
75. **THAILAND**
Society of Aesthetic Plastic Surgeons of Thailand (THSAPS)
76. **TURKEY**
Turkish Society of Aesthetic Plastic Surgery (TSAPS)
77. **UKRAINE**
Ukrainian Association of Plastic, Reconstructive and Aesthetic Surgeons (UAPRAS)
78. **UKRAINE**
Ukrainian Society of Aesthetic Plastic Surgeons (USAPS)
79. **UNITED ARAB EMIRATES**
Emirates Plastic Surgery Society (EPSS)
80. **UNITED KINGDOM**
British Association of Aesthetic Plastic Surgeons (BAAPS)
81. **UNITED KINGDOM**
United Kingdom Association of Aesthetic Plastic Surgeons (UKAAPS)
82. **UNITED STATES**
American Society for Aesthetic Plastic Surgery, Inc. (ASAPS)
83. **VENEZUELA**
Sociedad Venezolana de Cirugía Plástica, Reconstructiva, Estética y Maxilofacial (SVCPREM)
84. **VIETNAM**
Vietnamese Society of Aesthetic and Plastic Surgery (VSAPS)

GLOBAL ACCREDITATION



OZAN SOZER - UNITED STATES
Chairman, ISAPS Global Accreditation Committee

Dear ISAPS Members,

The Global Accreditation Program was initiated by former ISAPS President Dr. Renato Saltz almost three years ago. After months of hard work and multiple meetings, we had a solid game plan in place and were close to beginning the program when COVID-19 brought everything to a standstill.

At the beginning of the year, we decided it was time to return to the program. I believe that with the pandemic we have realized the importance of maintaining a safe surgical facility. While hospitals were flooded with COVID-19 patients and elective procedures were suspended, outpatient surgery centers became the only places we could practice. In these centers we were able to offer our patients a safer environment than many hospitals could provide.

In light of this, ISAPS is embarking on a renewed collaborative effort with the American Association for Accreditation of Ambulatory Surgery Facilities (AAAASF) to provide accreditation of surgical facilities worldwide. AAAASF has actually been working with ISAPS since 2005 to find ways to improve patient safety around the world. Its program was first initiated in 1980 and has since been approved throughout the United States and internationally by the ISQua External Evaluation Association and the United Arab Emirates. AAAASF has also contributed to European norms for quality and safety.

The accreditation process is intended to demonstrate unequivocally to the public as well as to the medical community that approved surgical facilities strictly comply with a rigorous set of standards and provide the safest care possible. With the Global Accreditation Initiative, qualified and responsible plastic surgeons will be able to distinguish themselves from non-accredited facilities. In addition, the program will help reframe the conversation and media coverage around any adverse events.

Now is a critical time for us all to commit to elevating care through accreditation, and this program is our vehicle to do so. In the coming months we will be providing additional information about patient safety and accreditation and we will be holding various accreditation-themed events. I strongly encourage you to seek out more information and to join us for these events, and ultimately to have your facilities accredited through the ISAPS-AAAASF Global Accreditation Initiative.

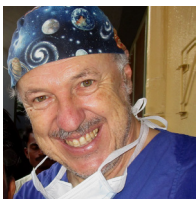



Figure 1: INTERPLAST visit in the refugee camps of Northern Iraq.

HUMANITARIAN

SUPPORT IN NORTHERN IRAQ



ANDRÉ BORSCHÉ
GERMANY

INTERPLAST-Germany was founded in 1980 and stands for international plastic reconstructive surgery in developing countries. As a non-governmental organization for humanitarian aid, the group organizes operative camps for plastic surgery all over the world. In the last 40 years, the teams of INTERPLAST have operated on more than 100,000 patients throughout 1,500 missions and have run hospitals in Nepal and Africa. Regular and consecutive surgical camps are required in each place. While there, operating surgeons perform basic plastic surgery techniques and teach procedures to local surgeons so they can better help their own people and improve the effectiveness of their dedication.

Plastic surgeons from INTERPLAST-Germany were invited by the Barsany Charity Foundation (BCF) to visit Erbil in Northern Iraq. BCF takes care of around 700,000 refugees

in various camps and provides medical support to hundreds of people in need. As German doctors, we were impressed by the enthusiasm and expertise of the local medical workers and doctors which look after the refugees. In order to support the camps, who lack many medical materials, we provided them with extra medications, bandages, surgical instruments, and even financial donations. In addition, thanks to our collaboration with the NGO Wings of Help, we were able to donate 250,000 protective face masks.

Our past experiences from INTERPLAST missions to Amman, Jordan and from an ISAPS mission to Reyhanli, Turkey demonstrated the urgent need for plastic and reconstructive surgery among refugees, who are often traumatized and challenging to treat. In Erbil, we met experienced plastic surgeons who took excellent care of their patients. These

surgeons ran a burn unit and provided emergency life-saving medical treatment to refugees. However, many reconstructive procedures were limited due to financial reasons. Our colleagues in Erbil showed us many patients with severe burn sequelae, hypertrophic scars, and post-burn contractures who would benefit from further plastic surgery. Our team discussed the technical details of possible procedures and issues that may arise post-care with them.

Among refugees, the rate of suicide is very high. Often, people set themselves on fire with kerosene, but they do not always succeed in killing themselves. Instead, they end up in a situation where they are now physically and psychologically suffering. Plastic reconstructive surgery may help burn patients overcome their trauma and improve their functional and aesthetic appearance. INTERPLAST helps

by providing surgical items like expanders and purchasing compression garments. In certain severe cases, we may work together with local surgeons or handle the treatment.

Humanitarian aid in the field of plastic surgery should not only remain a local task but also grow into a worldwide activity to provide the most effective aid. If we share our experiences from these missions and are more transparent about our activities with each other, we will all benefit. This will help us learn about problems and about how to manage them better. The humanitarian goals of ISAPS underline the importance of collaboration with other charitable organizations. INTERPLAST-Germany will take an active part in this process of coordination, improving communication, and showing respect for other individuals engaged in humanitarian plastic surgery.



Figure 2: Dedicated medical workers in the refugee camp.

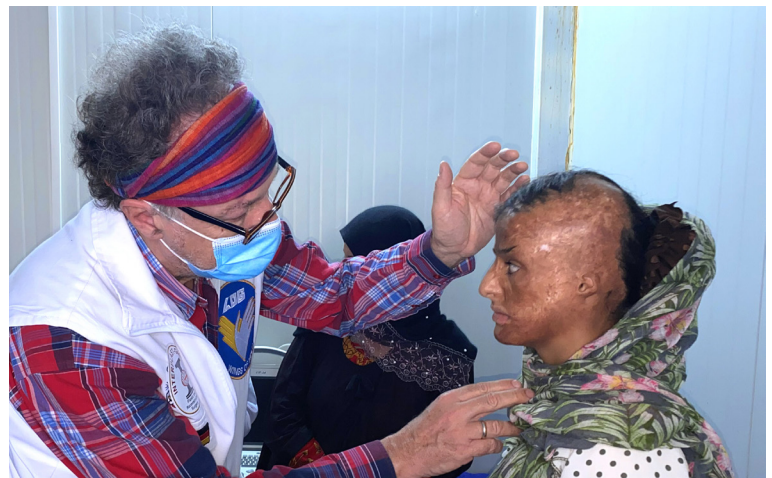

Figure 3: Disfigurement after burn trauma.

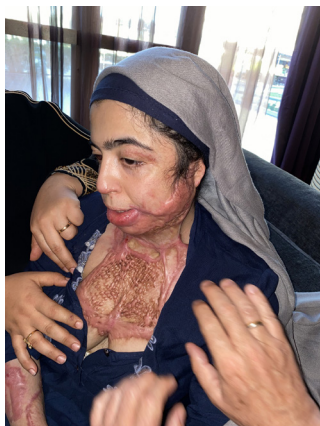

Figure 4: Severe burn sequelae after a suicide attempt.



Figure 5: Meeting the plastic surgeons in Erbil.



Figure 6: Donating medical items from INTERPLAST.



MemoryGel® Breast Implants Are Safe and Effective^{1¥}



#1
Global Brand²

7
MILLION+
Women with MENTOR®
Breast Implants³

MemoryGel® Core Study Highlights

Highest
Patient Satisfaction^{§4}

97%

Patients indicated that they would
make the same decision to have
breast implant surgery at 10 years

Low

Reported Kaplan-Meier estimated cumulative incidence of key
complications at 10 years for round gel implants among the primary
augmentation cohort^{*5}

[¥]MemoryShape Post-Approval Cohort Study (formerly Contour Profile Gel Core Study) Final Clinical Study Report. Mentor Worldwide, LLC; 02 June 2015. MemoryGel Core Gel Clinical Study Final Report. Mentor Worldwide, LLC; April 2013. Mentor MemoryShape Post-Approval Continued Access Study (formerly Contour Profile Gel Continued Access Study), Final Report. October 2014. Mentor MemoryGel Breast Implant Large Post Approval Study Re-Op Phase Annual Report. 17 June 2016. Adjunct Study Final Report for Mentor's MemoryGel Silicone Gel-filled Breast Implants. 02 November 2012. Mentor MemoryShape CPG Styles Study: A Study of the Safety of the Contour Profile Gel Breast Implants in Subjects who are Undergoing Primary Breast Augmentation, Primary Breast Reconstruction, or Revision, Final Clinical Study Report. 20 October 2015.

[§] Based on patient survey at 10 years in the Mentor® MemoryGel™ Breast Implant 10-Year Core Gel Clinical Study Final Report

^{*} Not a head to head clinical study. Based on a comparison of 10 year core clinical study data for Primary Augmentation, Revision Augmentation, and Primary Reconstruction for MENTOR® MemoryGel® Breast Implants and NATRELLE™ Round TruForm® Gel Breast Implants

1. MemoryShape Post-Approval Cohort Study (formerly Contour Profile Gel Core Study) Final Clinical Study Report. Mentor Worldwide, LLC; 02 June 2015. MemoryGel Core Gel Clinical Study Final Report. Mentor Worldwide, LLC; April 2013. Mentor MemoryShape Post-Approval Continued Access Study (formerly Contour Profile Gel Continued Access Study), Final Report. October 2014. Mentor MemoryGel Breast Implant Large Post Approval Study Re-Op Phase Annual Report. 17 June 2016. Adjunct Study Final Report for Mentor's MemoryGel Silicone Gel-filled Breast Implants. 02 November 2012. Mentor MemoryShape CPG Styles Study: A Study of the Safety of the Contour Profile Gel Breast Implants in Subjects who are Undergoing Primary Breast Augmentation, Primary Breast Reconstruction, or Revision, Final Clinical Study Report. 20 October 2015.

2. Mentor Worldwide LLC. GBI Data through Q1 2018 for Implants, Expanders and Sizers. Mentor Worldwide LLC. Mentor Worldwide Historical Implant Data Jun 2018 - Jan 2020. January, 2020.

3. Mentor Worldwide LLC. Mentor Worldwide Historical Implant Data Jun 2018 - Jan 2020. January, 2020.

4. Mentor Worldwide LLC. MemoryGel® Core Gel Clinical Study Final Report, April 2013. p.67, para 5.5.3.

5. Spear, Scott, et al. Natrelle Round Silicone Breast Implants: Core Study Results at 10 Years. *Plas Reconstr Surg*. 2014;133(6):1354-1361 Health Canada: Summary Basis of Decision (SBD) for Natrelle™ Highly Cohesive Silicone- Filled Breast Implants. Application No. 88573. License No.72262. Date Issued: 2014/01/17. Health Canada: Summary Basis of Decision (SBD) for Natrelle™ Silicone- Filled Breast Implants- Smooth Shell With Barrier and Natrelle™ Silicone Filled Breast Implants- Textured Shell with Barrier Layer. Application No. 61865 and 60524 License No License No 72264 and 72263. Date Issued: 2012/09/25. MENTOR Worldwide LLC. MemoryGel® Core Gel Clinical Study Final Report, April 2013 FDA: Sientra, Inc. Summary of Safety and Effectiveness Data (SSED). Santa Barbara, Calif: Sientra; 2012.

IMPORTANT SAFETY INFORMATION MENTOR® MemoryGel® Breast Implants are indicated for breast augmentation, in women who are at least 18 years old, or for breast reconstruction. Breast implant surgery should not be performed in those women with active infection anywhere in their body, those with existing cancer or pre-cancer of their breast(s), those who have not received adequate treatment for these conditions or those who are pregnant or nursing. There are risks associated with breast implant surgery. Breast implants are not lifetime devices and breast implantation is not necessarily a one-time surgery. The most common complications with MENTOR® MemoryGel® Breast Implants include re-operation, implant removal, capsular contracture, asymmetry, and breast pain. A lower risk of complication is implant rupture, which is most often silent. The health consequences of a ruptured silicone gel-filled breast implant have not been fully established. Screenings such as mammography, MRI, or ultrasound are recommended after initial implant surgery to assist in detecting implant rupture. Breast implants are also associated with the risk of breast implant anaplastic large cell lymphoma (BIA-ALCL), an uncommon type of lymphoma and an individual's risk of developing BIA-ALCL with MENTOR® Breast Implants is considered to be low. Your patient needs to be informed and understand the risks and benefits of breast implants, and she should be provided with an opportunity to consult with you prior to deciding on surgery. For detailed indications, contraindications, warnings and precautions associated with the use of all MENTOR® Implantable Devices, please refer to the Product Insert Data Sheet provided with each product or review the Important Safety Information provided at www.mentorwllc.eu.

<https://www.injmedicaldevices.com/en-EMEA/companies/mentor>

www.mentorwllc.eu This publication is not intended for distribution outside of the EMEA region.

The third-party trademarks used herein are the trademarks of the respective owners.

© Mentor Worldwide LLC 2021 164631-210115 EMEA

NS CHAIR REPORT

DEVELOPING POWERFUL COMMUNICATION WITH MEMBERS THROUGH THE NS NETWORK



MICHEL ROUIF - FRANCE
ISAPS Chair of National Secretaries

The second virtual ISAPS National Secretaries Meeting was held on Saturday, January 9th. About 60 countries had their National Secretary (NS) present for the first NS meeting of the year. We are now more familiar and more comfortable with the technology and I am positive that this quarterly meeting is slowly becoming a “gold standard” for our NS family, especially during the COVID-19 times.

After presentation of the 2020-2021 Board of Directors by ISAPS President, Nazim Cerkes, the new projects for 2021 were presented. Sarah Johnson, our new Executive Director, also introduced her executive office team. Richard Guy, who is responsible for managing all things relating to membership since October 2020, attended the NS meeting, as one of the critical topics was membership renewal.

During the first NS meeting of the year, we focused on three topics of discussion. For 10 minutes each, three board members presented their work to the National Secretaries. Vakis Kontoes, Chairman of the Membership Committee, gave an update on membership renewal, including the new, upcoming fast-track process. Ozan Sozer, Chairman of the Education Council, presented this year’s new educational program, highlighting individual webinars and courses such as digital ISAPS symposia, an ISAPS Business School event, and ISAPS WORLD on March 27-28. The accreditation program, originally initiated in 2019-20, is being revived and all National Secretaries are invited to join and support this program. Finally, Fabian Cortiñas, Chairman of the Communication Committee, explained the society’s ongoing efforts on social media.

For the second part of the meeting, three discussion groups were held simultaneously in separate Zoom rooms with about 18 National Secretaries attending each 40-minute workshop.

One board member was invited to join each group and get insight on the topic. Each group then had five minutes to present a summary in the plenary session. I want to thank all the National Secretaries and our Assistant Chair Bertha Torres (NS, Mexico) for the great work they did in all three workshops.

Education and Accreditation Chair, Gustavo Abrile (NS, Argentina), invited Ozan Sozer, who presented the unique global nature of ISAPS WORLD, which will feature 48 hours of live sessions and 400 faculty members. Dr. Abrile highlighted that this is the most important focus of Q1 and a unique opportunity for global collaboration.

For Membership and Development, Babak Nikoumaram (NS, Iran) invited Vakis Kontoes and Richard Guy. Topics included marketing strategies to attract new members, feedback on the NS applicant review process, tools to promote membership renewal, the upcoming fast-track process, and the new Residents Program.

For Communication and Marketing, Francesca de Angelis (Assistant NS, Italy) and Naveen Cavale (NS, UK) invited Fabian Cortiñas. This group’s discussion focused on how to promote ISAPS to patients in different countries and how to combat issues arising from medical tourism.


This time spent with the National Secretaries, several board members, and the executive office team was a wonderful opportunity to move ISAPS forward. Listening to one another, bringing in new ideas from both sides, and creating a spirit of unity strengthen ISAPS’ development.

The next online National Secretaries Meeting will be held in April-May 2021.

Be safe with friends and family.

ISAPS JOURNAL

MESSAGE FROM THE EDITOR-IN-CHIEF



BAHMAN GUYURON
UNITED STATES

2020 will be remembered as a year that changed our lives immeasurably. The sorrow that many of us feel from losing loved ones cannot be described in words. Around the world, practices were shut down for long periods of time. However, our ingenuity as plastic surgeons and our prudent use of time never ceased.

The energy that was ordinarily used in the operating room while performing surgeries was instead channeled towards scholarly activities, research, and the preparation of articles. This culminated in many medical journals seeing an increase in paper submissions. In fact, the number of submissions to our journal, *Aesthetic Plastic Surgery*, which has been increasing annually since I first assumed my position, increased by nearly 200% compared to my commencement year.

While COVID-19 is definitely a factor in the surge of article submissions, it is not the main reason that our number of submissions has gone up so colossally. Those of you who have been reviewing articles have contributed to our success inestimably. It has not gone unnoticed by authors that our turnaround time has greatly decreased. In fact, our current



turnaround time from article submission to first decision is a mere 14 days. According to the publisher's report, this is the shortest amount of time amongst the over 2,000 Springer journals. What is even more fascinating is that this is 50% faster than the second-best time listed in the report.

Your sagacious selection of articles also resulted in an increase in our journal's impact factor in 2020. Despite all this growth, we cannot simply be content, and we will continue to work towards improving our journal. Our goals for the journal include improving the quality of its articles, raising its impact factor, advancing the audiovisual effect of

the journal by adding more videos, increasing our presence on social media, and most importantly, making sure that your expectations from your journal are met.

You can be part of our crusade to make *Aesthetic Plastic Surgery* the best source of aesthetic plastic surgery information out there by volunteering to review articles. On behalf of our entire team, I would like to thank you for your support. We wish you safety and success in 2021.

GUEST ARTICLE FROM ISAPS GLOBAL SPONSOR



COMMITTED TO YOU, AND MILLIONS OF PATIENTS WORLDWIDE

GC Aesthetics® Ltd. (GCA) is a global medical device company based in Europe with two state-of-the-art manufacturing sites and systems in place to ensure the safety of our products through pre-clinical testing, clinical studies, and excellent global post-market surveillance, as well as continuous audits in our manufacturing sites: covering quality, technical, operational, microbiological, clinical, and regulatory data and processes.

With **over 40 years of expertise** in aesthetics and **more than three million implants** fitted over the last 10 years¹ **we are proud of our 10-year clinical data:** long-term proven safety in the only two large scale prospective European studies of breast implants, with 10 years of patient follow-up.

Our vision and values focus on safety, quality and reliability. We will continue to build on our strong reputation by innovating, listening, and improving as we strive to become the most-trusted and first-choice provider of surgical aesthetics.

In our commitment to be **A Confident Choice for Life™** we have evolved from breast implant suppliers to Solution Providers, supporting Surgeons and Patients with pre-surgery, surgery and post-surgery products.

With you, at every level of care:

Pre-surgery: Even before the surgery, GC Aesthetics supports patients and surgeons during the consultation. With **Eve 4.0™**, our interactive digital platform, and the GCA consultation kit, we offer products to aid the surgeon's explanation, help the patient better manage expectations and make a fully informed decision about surgery.

Surgery: GCA is your reliable partner for breast and body implants and surgical support. Backed by years of continuous research and development, GC Aesthetics offers the largest and most comprehensive range of silicone breast implants for aesthetic, reconstruction, and revision breast surgeries.

GCA offers: Anatomical and Round Breast Implants with different surfaces including Smooth, Smooth Opaque & Textured. Our most recent launch, **PERLE™** the (r)evolutionary smooth opaque round breast implant & **HydroCone™** a sterile, single patient use implant insertion device are two products that in combination will help surgeons achieve better outcomes reducing risk of complications.^{2,3}

Post-surgery: GCA support goes further than the operation alone. We know that recovery is just as important as the surgery itself. Our **NOA™** compression garments ensure optimum results post-surgery for patients' comfort, and our **GCA Comfort Plus™ Warranty** provides a comprehensive lifetime warranty on all GCA breast implants.

Through a culture of continuous innovation and dedication, GCA continues to strive to be the long-term partner-of-choice for both surgeons and patients.

REFERENCES

1. Internal Data, GC Aesthetics, 2020
2. Montemurro, P. et al (2020). Controllable factors to reduce the Rate of Complications in Primary Breast Augmentation: Review of the Literature. *Aesthetic Plastic Surgery*.
3. Montemurro, P. et al (2019). Implant insertion time and incision length in breast augmentation surgery with the Keller Funnel: Results from a comparative study. *Aesthetic Plastic Surgery*. 43: 881 - 889.

IN MEMORIAM

DR. EDWARD ABDEL NOUR, MD (1950-2021)



EDWARD ABDEL NOUR

On Sunday, February 28th, Dr. Edward Abdel Nour passed away at the Hotel Dieu de France University Hospital, after a long battle against COVID-19. The news came as a shock to the Lebanese plastic surgery community. Dr. Abdel Nour was a well-trained and prominent plastic surgeon and was highly regarded for his service and expertise. He was known for his kindness and caring with all his patients.

Dr. Abdel Nour was born in 1950 and graduated from Saint Joseph University Medical School in Lebanon. He also received

his plastic surgery training at Saint Thomas' Hospital in London. After returning to Lebanon in 1992, he developed a busy private practice, and also served as a mentor to many plastic surgeons. He first joined ISAPS in August 1999 and regularly attended ISAPS meetings. I remember we met frequently at many international conferences.

Dr. Abdel Nour is survived by his wife, the well-known pediatrician Dr. Hoda, and his sons Raja and Richard.

HISTORY

FRANKENSTEIN, THE AESTHETIC FAILURE¹



DENYS MONTANDON
SWITZERLAND

"I perceived in the gloom a figure which stole from behind a clump of trees near me; I stood fixed, gazing intently: I could not be mistaken. A flash of lightning illuminated the object, and discovered its shape plainly to me; its gigantic stature, and the deformity of its aspect, more hideous than belongs to humanity, instantly informed me that it was the wretch, the filthy dæmon, to whom I had given life."

Mary Shelley's Frankenstein




Figure 1:
Mary Godwin-Shelley.

Since its first publication in 1818, the tale of Frankenstein, written by a 19-year-old woman (**Figure 1**), has not ceased to fascinate humanity. Today, Mary Shelley's *Frankenstein* is considered a literary classic. In 2019, the BBC labeled it one of the 100 most inspiring novels. It has inspired numerous literary essays, articles, novels, theater plays, movies, TV shows, drawings, paintings, and sculptures. 'Frankenstein' itself has become a well-known word, often used to describe a monster or to symbolize horror. The book has been analyzed and dissected by philologists, historians, philosophers, psychoanalysts, and science fiction experts, and has been applied to major questions of the time, like the French Revolution, the abolition of slavery, and plague epidemics. In this day and age, it resonates as a warning for the potential dangers of new technologies like human cloning or artificial intelligence. But it may also transmit a message to plastic and reconstructive surgeons.

GENEVA, 1816: WHERE IT ALL STARTED

"I am by birth a Genevese, and my family is one of the most distinguished of that republic." So begins the narrative of doctor Victor Frankenstein.

In the spring of 1816, Lord Byron and his lover, John Polidori, fled scandal and left England for Geneva. There they were joined by the poet Percy Shelley, Mary Godwin, and Mary's stepsister Claire Clairmont (**Figures 2a-2d**). All of them were followers of free love; moralizers called them the "League of Incest." By summertime, Clairmont was pregnant by Byron, who had left his pregnant wife and daughter in England. The 18-year-old Mary Godwin, daughter of the radical thinker and feminist writer Mary Wollstonecraft and the liberal philosopher William Godwin, was now pregnant with Shelley's child, whom she married a year later.



Figure 2a:
Lord Byron.



Figure 2b:
Percy Shelley.



Figure 2c:
John Polidori.



Figure 2d:
Claire Clairmont.

In Geneva, the group rented a splendid villa dominating the lake, just outside the city (**Figure 3**). However, the eruption of Mount Tambora had created "a year without a summer" and it was cold and rainy. To satisfy their romantic aspirations, they visited the suburbs of Geneva, climbed Mont Blanc to see the Sea of Ice, and sailed on Lake Geneva amidst dreadful storms. They turned to reading, drinking and sex - but Byron was bored. One evening, he announced, "We will each write a ghost story."

¹ This article was published in the Journal of Craniofacial Surgery in April 2020. It is reproduced with permission from the Editor, Mutaz Habal.



Figure 3: Villa Diodati, near Geneva.

“The noble author began a tale, a fragment of which he printed at the end of his poem of Mazeppa. Shelley commenced one founded on the experiences of his early life. Poor Polidori had some terrible idea about a skull-headed lady, who was

so punished for peeping through a key-hole...” Mary’s inspiration came to her in a dream. Originally intended to be a short story, her ghost story became a book in three volumes after encouragement from Shelley. She was still nursing when she began writing her novel and was pregnant again by the time she finished in May 1817. Frankenstein was published anonymously in 1818, not least out of a fear that she might lose custody of her children.

The first theatrical production of Frankenstein was staged in London in 1823. The story became an immediate sensation, but was also criticized for its radicalism and its Byronic impieties. Critics called it “a tissue of horrible and disgusting absurdity, radically unhinged and immoral.” The first popular edition was published in 1831, heavily revised and shortened to make it less scandalous, with a new preface in which Mary writes: *“How I, then a young girl, came to think of, and to dilate upon, so very hideous an idea.”*

THE STORY

Born into a wealthy Genevan family, Victor Frankenstein is encouraged by his father to seek a greater understanding of the world through chemistry. Since childhood, he has been obsessed with studying outdated theories simulating natural wonders. Sent by his father to university in the German city of Ingolstadt, he excels at chemistry and other sciences, soon developing a secret technique to impart life to non-living matter. Collecting pieces of cadavers and using a combination of ancient and modern methods, he undertakes the creation of a humanoid and brings him to life. Despite Victor designing him to be beautiful, upon animation the creature is instead “a hideous giant, with watery white eyes and yellow skin that barely conceals the muscles and blood vessels underneath” (Figure 4).



Figure 4: Statue of the monster in the city of Geneva, where he committed his crimes.

To Victor’s despair, the creature soon disappears. Victor returns to Geneva, where he learns that his younger brother has been killed in a strange manner. A young girl is accused of the crime, but Victor suspects his wretched creature to be the culprit. Ravaged by grief and guilt, Victor retreats into the mountains close to Mont Blanc. The creature finds him there and pleads for Victor to hear his tale. He then relates his first days alive, of being alone in the wilderness and discovering that people were afraid of and hated him due to his appearance. He learned to speak by living near a poor family for months and taught himself to read using a lost satchel of books he found in the woods. After seeing his reflection in a pool, he realized that he was hideous and that he was as terrified of himself as other humans were.

The creature explains that he tried to love and help the humans, but he was always rejected. He shares with Victor his distress that he will never be part of human society and asks him to fashion a female mate for him so that he can retire to the deserts of South America, where he will never meet or harm another human. Victor agrees and moves to the Orkney Islands to begin his task, where he suspects that the creature has followed him. Out of fear that creating a female creature might lead to the breeding of a race that could plague mankind, Victor tears apart the unfinished female creature.

Out of revenge, the creature strangles Victor’s best friend and, the day after Victor’s wedding, strangles his wife. Victor attempts to catch him and pursues him all the way to the North Sea, where he collapses from exhaustion and hypothermia. He is rescued by a British ship and dies on board. After discovering Victor’s death, the creature vows to kill himself so that no one else will ever know of his existence. The creature drifts away on a piece of ice that is soon “lost in darkness and distance,” never to be seen again.

ALCHEMY

Despite her extraordinary education in philosophical and political matters as well as in literature and poetry, Mary had little scientific background. However, she recalls in the novel’s preface: “During one of the conversations between Lord Byron and Shelley, various philosophical doctrines were discussed, and among others the nature of the principle of life, and whether there was any probability of its ever being discovered and communicated. They talked of the experiments of Dr. Darwin...”

Perhaps she was also inspired by Geneva, which at that time was a center for scientists. In the novel, Victor Frankenstein mentions his passion for the occult and modern sciences: “Natural philosophy is the genius that has regulated my fate; I desire, therefore, in this narration, to state those facts which led to my predilection for that science.” During his studies in Ingolstadt, he refers to several renowned natural scientists including Albertus Magnus, Cornelius Agrippa, and Paracelsus, and confesses: “I read and studied the wild fancies of these writers with delight; they appeared to me treasures known by too few besides myself. I have described myself as always having been imbued with a fervent longing to penetrate the secrets of nature.”

Although less well-known today, these three scientists were known for their ideas on transforming matter and creating elixirs of life. They are considered pioneers in the field of natural science and early contributors to today’s pharmaceutical industry.

Albertus Magnus (1200-1280) was a German Dominican friar and bishop known for his encyclopedic knowledge and writings on topics such as logic, botany, geography, astronomy, astrology, mineralogy, alchemy, zoology, and physiology. Magnus is said to have discovered the philosopher’s stone, a legendary substance capable of turning base metals into gold that is also known as the elixir of life, as it enables the achievement of immortality.

Cornelius Agrippa (1486-1536) was a German polymath, physician, legal scholar, soldier, theologian, and writer. He is best known for his writings on occult philosophy and for his book *On the Nobility and Excellence of the Feminine Sex*, in which he tried to prove the superiority of women using cabalistic ideas. Nicknamed the Archimagus, Agrippa also spent time in Geneva as a physician.

Paracelsus (1494-1541) was a Swiss physician and alchemist. A crude and superstitious empiricist, Paracelsus was known for being an alchemist and astrologer as well as a megalomaniac wanderer and for peddling pamphlets, Bibles and self-portraits in Austria, Germany, and Italy. In 1526, Paracelsus was appointed as the city of Basel’s doctor. He was also a provocateur, and during the feast of St. John in 1527, he threw the works of Galen and Avicenna onto a fire, proclaiming: “Go to the fire of St. John and let all that is bad disappear into the air with your smoke!” He urged his students to abandon this “dead knowledge” and to apply themselves only to the study of nature. He is credited as one of the fathers of pharmacology

and as the inventor of the painkiller laudanum, also called the wine of opium.

Johann Konrad Dippel (1673-1734) is not mentioned in *Frankenstein*, but it is probable that Mary had heard about him. Dippel was born at Castle Frankenstein near Darmstadt, Germany. He was a pietist, theologian, physician, alchemist, and occultist who led an adventurous life, often getting into trouble due to his controversial opinions and problems managing money. He was eventually imprisoned for heresy and served a seven-year sentence. Dippel also created Dippel’s oil, which was supposed to be equivalent to the elixir of life. In his dissertation *Maladies and Remedies of the Life of the Flesh*, he claimed that souls could be transferred from one corpse to another by using a funnel.

ELECTRICITY

In *Frankenstein*, young Victor narrates: “[Following a storm in Geneva] we found a tree shattered in a singular manner. The catastrophe of this tree excited my extreme astonishment, and I eagerly inquired of my father the nature and origin of thunder and lightning. He replied “Electricity;” describing at the same time the various effects of the power. He constructed a small electrical machine and exhibited a few experiments.” Mary noted that one evening in the middle of summer in 1816, the discussions had turned to the principle of life, and to topics such as the re-animation of a corpse and galvanism. There is also speculation that the character of Victor Frankenstein was inspired by Percy Shelley, who had experimented with electricity and magnetism and with gunpowder and chemical reactions at school. Among the physiologists at the beginning of the 19th century, Galvani’s ideas had an immense influence on the understanding of animal motricity.




Figure 5: Luigi Galvani, with the body of a dead frog.

Luigi Galvani (1737-1798) was an Italian physician, physicist, biologist, and philosopher, as well as a lecturer on surgery and anatomy at the Academy of Sciences in Bologna (Figure 5). In the 1780s, Galvani and his wife connected the nerves of a recently dead frog to a long metal wire and pointed it toward the sky during a thunderstorm. With each flash of lightning, the




Figure 6: Galvani's experiment with electricity.

frog's legs twitched and jumped as if they were alive (**Figure 6**). Through such experiments, Galvani proved not only that dead muscle tissue could respond to external electrical stimuli, but that muscle and nerve cells possessed an intrinsic electrical force responsible for muscle contractions and nerve conduction

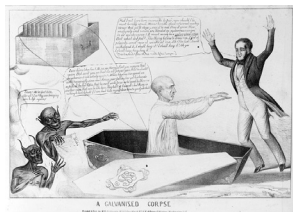


Figure 7: Aldini's re-animation of a cadaver.

in living organisms. Galvani named this newly discovered force "animal electricity" and laid the foundation for the modern fields of electrophysiology and neuroscience.

Galvani's nephew, Giovanni Aldini (1762-1834), was a physician and professor of physics in Bologna. His work was chiefly concerned with galvanism and its medical applications. Aldini's most famous public demonstration of the electro-stimulation technique of deceased limbs was performed on the executed criminal George Forster in 1803. *The Newgate Calendar* describes what happened to Forster's body: "On the first application of the [galvanic] process to the face, the jaws of the deceased criminal began to quiver, and the adjoining muscles were horribly contorted, and one eye was actually opened. In the subsequent part of the process the right hand was raised and clenched, and the legs and thighs were set in motion" (**Figure 7**). Mary was only five years old at the time, but this extraordinary experiment certainly influenced *Frankenstein*: "By the glimmer of the half-extinguished light, I saw the dull yellow eye of the creature open; it breathed hard, and a convulsive motion agitated its limbs."

AESTHETICS

Aesthetic values were very much connected to the Romantic era, which was at its peak from 1800 to 1850. The most characteristic romantic view is the idea that art and beauty should shape all aspects of human life. Considered fundamental to human existence, beauty and art should be a central ingredient not only in the lives of philosophers and artists, but also in the lives of ordinary men and women. **Figures 1 and 2a-2d** perfectly express this romantic search for beauty in the subjects' outfits, hairstyles, and presentation.

So, what happened following the reconstruction of Frankenstein's monster? "Oh! no mortal could support the horror of that countenance. A mummy again endued with animation could not be so hideous as that wretch. I had gazed on him while unfinished; he was ugly then; but when those muscles and joints

were rendered capable of motion, it became a thing such as even Dante could not have conceived." The creature, shaped from raw materials supplied by "the dissecting room and the slaughter-house," cannot be described by words other than "ugly wretch," "abhorred monster," "demon," "devil," "fiend," and "vile insect." With his ugliness, Victor's creature breaks the laws of nature. Although he can think, speak, read, and feel, his body is a failure due to "its form, gigantic in stature, yet uncouth and distorted in proportion." It is a living assembly of organs without respect for the aesthetic of nature. Its "ghastly and distorted" shape surpasses the limits of human normality. Victor himself is devastated when he first sees his creation: "Never did I behold a vision so horrible as his face, of such a loathsome yet appealing hideousness."

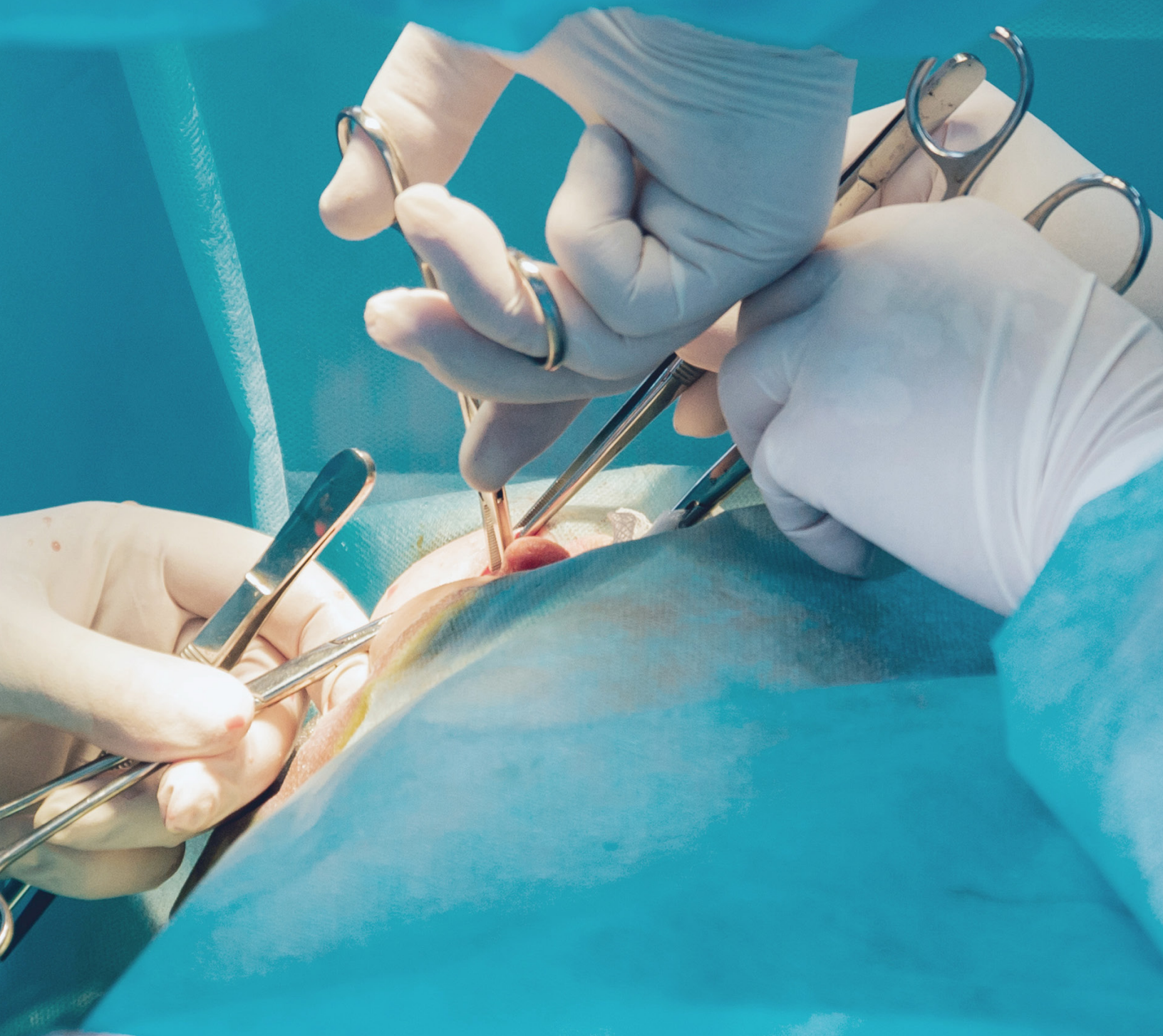
Mary took pains that the reader's sympathy would lie not only with Victor Frankenstein, but also with the creature, who is aware that his appearance arouses horror and suffers as a result. Hoping to fit in with regular people, the creature introduces himself to an old blind man who receives him without fear, but the drama arises as soon as he is seen by other people, who reject and banish him. His crimes are a consequence of the inhumanity linked to his appearance. Although born good, he has been treated so terribly that he has become a villain.

Victor Frankenstein himself is a genius plastic and reconstructive surgeon. He makes use of all the scientific knowledge available at the time and uses all kinds of methods, including bone transfers and fancy skin flaps. While he was able to animate his creature and to give him intelligence, the overall result was an aesthetic failure. He probably had no experience in aesthetic surgery!

Mary Shelley had a taste for the esoteric, the morbid, and the gothic. With *Frankenstein* she succeeded in crafting a tale that scares both children and adults more than 200 years later. But Mary herself was no stranger to tragedy. Throughout her life, she gave birth to four children, buried three, and lost another child to a miscarriage so severe that she nearly died of bleeding. While in Geneva, she learned that her half-sister Fanny Imlay had committed suicide. In 1822, her husband Percy, who had left her for Claire Clermont, embarked on a sailboat and drowned during a storm. A year earlier, John Polidori, weighed down by depression and gambling debts, had committed suicide by means of cyanide. In 1824, Lord Byron died of malaria in Missolonghi. As she later put it: "I am the last relic of a beloved race, my companions extinct before me."

BREAST REDUCTION

HOW I DO IT



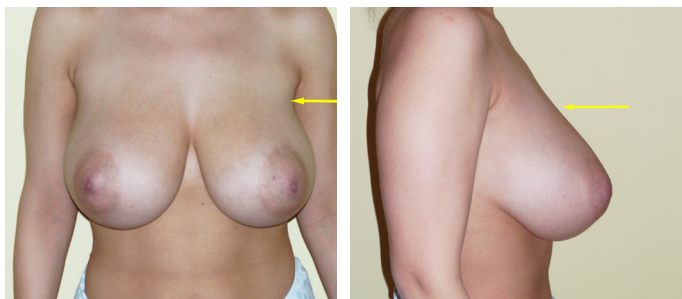
BREAST REDUCTION - A SIMPLIFIED APPROACH



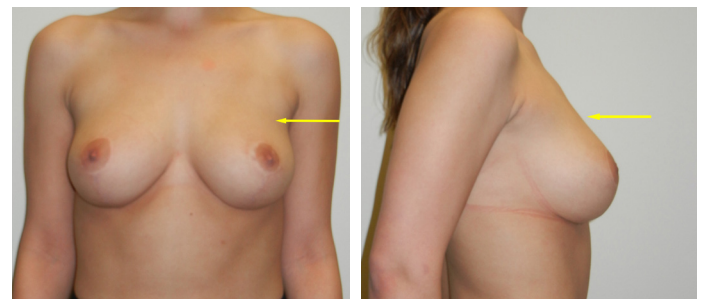
ELIZABETH HALL-FINDLAY
CANADA



GUSTAVO JIMÉNEZ MUÑOZ LEDO - MEXICO
ISAPS National Secretary, Mexico



Figures 1a, 1b: Frontal and lateral views of a 20-year-old patient who had 495 g and 455 g removed along with 150 cc of liposuction for final breast shaping.



Figures 1c, 1d: Patient at 18-month follow-up. The upper breast border (marked with a yellow arrow) did not change after the procedure.

INTRODUCTION

Breast reduction surgery using the true superomedial pedicle can provide consistent, predictable, and long-lasting results (Figures 1a-1d).

Although adding an inverted T-skin resection pattern is not needed as often as surgeons think, it may be necessary if there is too much poor-quality skin. Leaving the desired breast tissue attached to the upper skin flaps and removing the heavy inferior and lateral breast tissue respects the rules of gravity. The breast parenchyma is shaped, and the skin is not used as a brassiere.

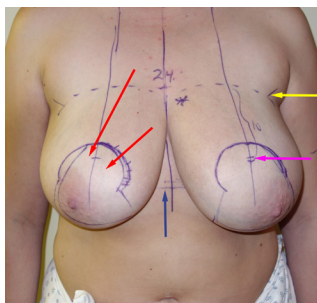


Figure 2a: The upper breast border is marked by a yellow arrow. The pink arrow shows the new nipple position. The vertical blue arrow shows the level of the inframammary fold at the level of the breast meridian.

MARKINGS

The upper breast border, marked by a yellow arrow, is a good landmark¹ because it does not change in breast reduction surgery (Figure 2a). Some patients have a high footprint, and some have a low footprint, and the footprint cannot be pushed up or held up with sutures.

The new breast meridian is not drawn through the existing

nipple but through the ideal breast meridian.

The new nipple position is marked at 10 cm below the upper breast border on the patient pictured in Figure 2a, who was 175 cm tall and weighed 80 kg. An ideal nipple is about 8-10 cm below the upper breast border in most patients and about the same distance from the chest midline.

The medial areolar opening and vertical limb are key to a good result. The lateral breast tissue is more mobile, so markings can be carried out laterally as much as needed to curve around any pigmented areolar skin. The surgeon should design the medial markings according to the Wise pattern² (Figure 2b).

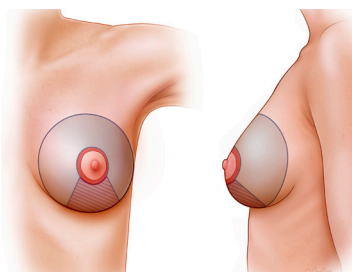


Figure 2b: Robert Wise designed a skin resection pattern based on a deconstructed brassiere. It is an excellent pattern for the parenchyma that should be left behind.

The areolar opening should be close to 16 cm as the areola will stretch to fit the skin opening.

The true superomedial pedicle has a dual axial blood supply. To include the descending artery from the second interspace, the base of the pedicle should be carried just past the breast

meridian into the lateral aspect of the areolar opening. Initially, the procedure was described using a medial pedicle, but it became clear that the strong descending branch was being unnecessarily sacrificed.^{3,4}

Because the inframammary fold (IMF) rises when weight is removed (even unintentionally) and closure of a vertical ellipse will push the vertical limbs superiorly and inferiorly, the vertical limbs should be joined together about 4 cm above the IMF.

TECHNIQUE

After the pedicle is de-epithelialized, an inferior wedge of skin and breast tissue is removed (**Figure 3a**). After leaving a 2-cm-thick lateral pillar, all the extra unwanted lateral breast tissue is removed.

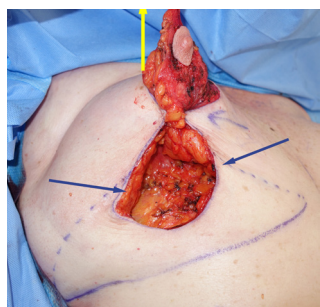

Figure 3a: An inferior vertical wedge of skin and breast tissue is removed, and any excess breast tissue is removed by pulling up on the pedicle (yellow arrow).

The first suture is placed in the inferior aspect of the areolar opening. The extent of resection as well as the breast shape can then be evaluated, and the pedicle can usually be easily inset. Any parenchyma that is blocking inset can be debulked. It is important to prevent compression and kinking of the pedicle to avoid problems with nipple-areolar necrosis. The blood supply is superficial as there is no blood supply through the parenchyma to the nipple in a superomedial pedicle.⁵

Pulling up on the pedicle as shown in **Figure 3a** will allow the pillars to fall together. The inferior border of the superomedial pedicle becomes the medial pillar. Pillar closure starts at the dotted line, not at the bottom of the skin opening and not at the IMF. The key is to produce a Wise pattern shape which can be left behind with no tension on the pillar closure. The breast should slide freely, and the lower end of the vertical incision should not be sutured down to the chest wall.

Note that the Wise pattern is marked with a dotted line in **Figure 3a**. All parenchyma and fat below and beyond the Wise pattern should be removed by direct excision and tailored out with liposuction. Liposuction is designed to remove any subcutaneous tissue that remains below what will end up as a nice curve, much like the underwire shape of a brassiere. It is important to leave fat on the underside of the skin flaps in order to prevent scar contracture from occurring.

The vertical skin closure should not be cinched, shortened, or gathered, as it stretches back out and the constriction of the skin

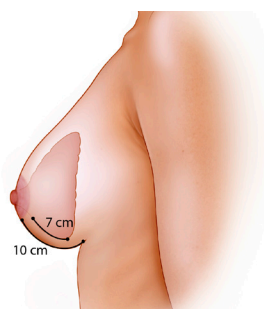
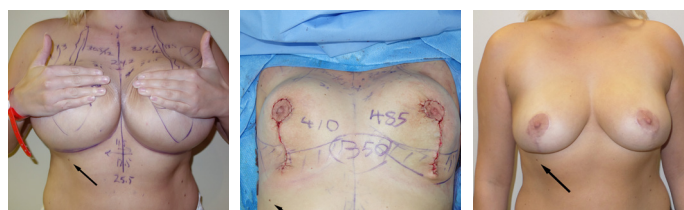

Figure 3b: On average, the pillars are about 7 cm long in a breast reduction, but the vertical skin can be over 10 cm in length because it tucks up behind the pillars.

edges can cause wound healing problems. Surgeons are often concerned about the length of the vertical incision. However, it is important to understand that while the pillars may be about 7 cm long, the skin is often 10 cm long or more and will tuck up behind the pillars (**Figure 3b**).

Drains are rarely used. The incisions are covered with paper tape and the patient is placed in a loose brassiere post-operatively (**Figures 4a-4c**).



Figures 4a, 4b, 4c. Patient from Figure 2a, post-breast reduction. The black arrow marks a mole showing how much the IMF was elevated just by weight removal. The cross-hatched lines in Figure 4b show where the tissue below the Wise pattern was removed.

SUMMARY

The true superomedial pedicle has an excellent dual axial blood supply and is one of the safest pedicles for a breast reduction procedure. In addition, this technique can be performed using either a vertical or an inverted T-type skin resection pattern. The result is predictable, consistent, and long-lasting because the removal of excess inferior and lateral parenchyma respects the effects of gravity.

The scars are the least important part. As surgeons, we should think about what we leave behind. That will tell us what we need to remove.

REFERENCES

1. Bolletta E, McGoldrick C, Hall-Findlay E. Aesthetic Breast Surgery: What Do the Measurements Reveal? *Aesthetic Surgery Journal*, 40: 742-752, July 2020.
2. Wise RJ. A preliminary report on a method of planning the mammoplasty. *Plast Reconstr Surg*;17:367,1956.
3. Hall-Findlay EJ. *Aesthetic Breast Surgery - Principles and Techniques*. Quality Medical Publishing, St Louis, Missouri, August, 2010.
4. Hall-Findlay EJ, Jiménez Muñoz Ledo G, Chapter 39, Vertical Breast Reduction and Re-Reduction, *Spear's Surgery of the Breast, Principles and Art, Fourth Edition*, Eds. Gabriel A, Nahabedian MY, Maxwell GP, Storm T; Wolters Kluwer, Philadelphia, Baltimore, New York, London, Buenos Aires, Hong Kong, Sydney, Tokyo, 2021.
5. Gheita A. Mammoplasty: The "Super Flap" or the Superior Pedicle Extra Long Flap for Massive Breasts with Marked Ptosis or Gigantomastia, *Aesth Plast Surg* 33: 461-470, 2009.



WALTHER JUNGWIRTH
AUSTRIA

MAMMARY REDUCTION & MASTOPEXY

HOW I DO IT WITH THE 'ADOPTED CIRCUMVERTICAL TECHNIQUE'

Throughout the last 25 years, I have relied on one technique as my go-to in mastopexies and mammary reductions: the adopted circumvertical technique. Let me tell you how I got there.

During my residency, we learned the Hoehler-Pitanguy vertical pedicle T-scar technique. I found LeJour interesting but disliked that soon after surgery, bottoming-out would often occur. This is a logical occurrence due to the fact that the entire skin circumference is tightened when making a vertical 5 cm scar. At the time, I found Mottura's work regarding the circumvertical reduction technique interesting. The advantage to this technique is that most of the remaining skin tissue is gathered around the areola instead of in the vertical scar. Thus, I adopted the circumvertical technique using my "Dirndl"-suture (2-0 Monocryl). The name for this suture comes from a traditional

Austrian dress, called a dirndl, where an overlapped vertical suture holds the body and breast of the woman in shape.

It is astonishing that over the years, I have never needed another approach. However, there are certain issues to consider when using this technique (**Figure 1**). For one thing, the marking cannot be measured as it can be when using different techniques (**Figure 2**). Instead, accurate marking comes with experience. Of course, the distance between the sternal notch and the upper pole of the areola is between 17-22 cm, but the extension of lateral de-epithelialization must be chosen carefully (**Figure 3**).

At the end of the procedure we see more volume in the upper pole region and a relatively flat lower pole. This must be explained in detail to your patients, and to your OR team.

During the first postoperative week most of the volume is in one place, but it takes 3-6 months until the breast looks round and full (**Figure 4**). I think this is one of the method's great advantages, because it uses gravity to get the final - and lasting - shape. It is important to remind your patients that the goal is not to look good immediately following the procedure, but rather that your breasts look good over the next few years. With this technique bottoming-out is very rare, as only 6 cm of skin distance is gathered in a 4 cm vertical scar.

Another important point to make about the adopted circumvertical technique is that the base of the breast becomes up to 40% smaller. This is because the skin envelope as well as the breast

tissue are gathered in the vertical line. The skin is gathered by lateral de-epithelialization, the tissue by the central dirndl-suture. To adapt the wide diameter of skin gathered around the areola, it is necessary to use a 0-pds slowly absorbable Benelli suture and a running 3-0 Prolene periareolar suture. I do not use drains, just adhesive strips, and a medical bra.

In the over 1,000 cases we have performed using this technique, there has been a low complication rate. To prevent problems with the healing of the wound, I cut a little extra pedicle at the point where the areola is attached to the vertical cut. As a result, we have never had areola necrosis, since this technique leaves 80% of the pedicle intact.

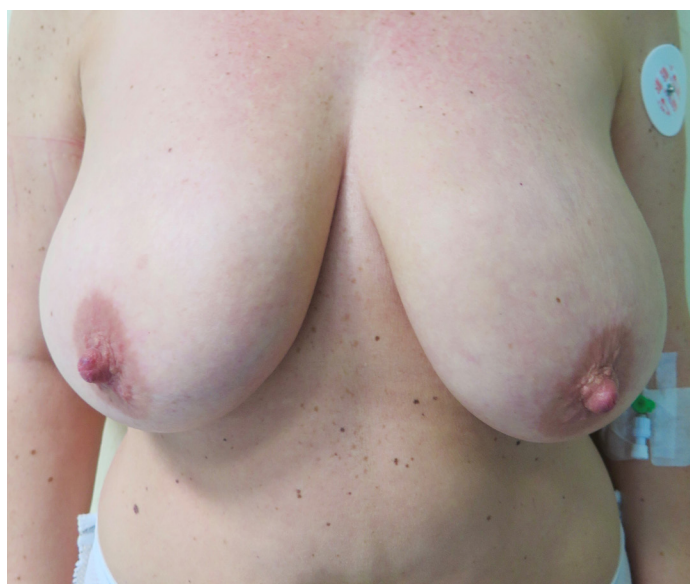

Figure 1: Preoperative patient, 49 years old.

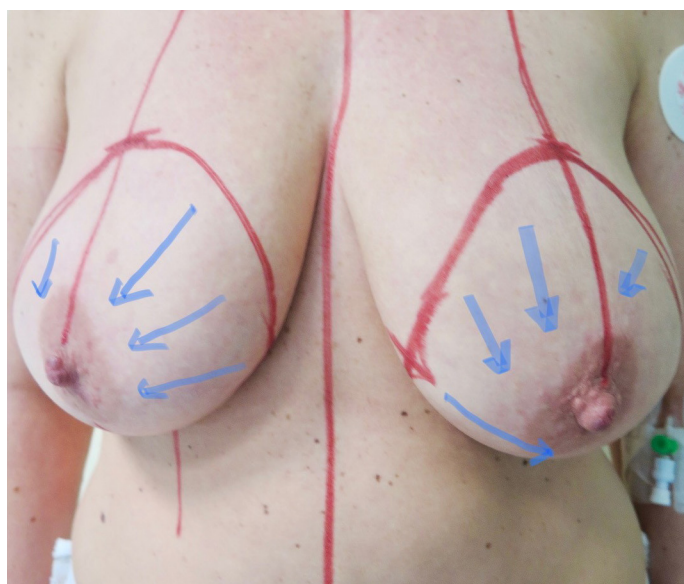


Figure 2: Preoperative patient with markings.

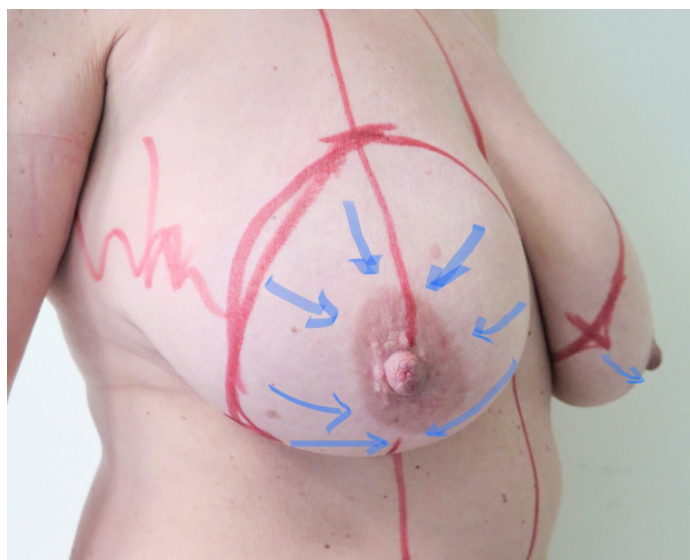


Figure 3: Side view of de-epithelialization.

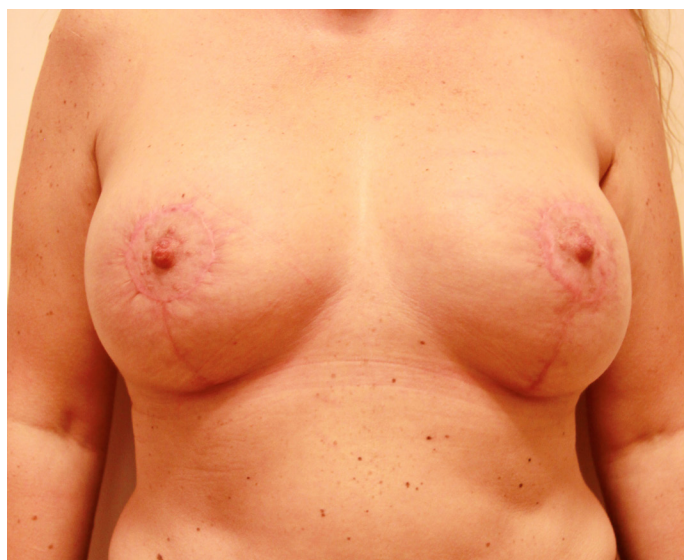

Figure 4: Postoperative patient. Patient has a short periareolar scar and a vertical scar.



MARISA
MANZANO SURROCA - SPAIN

EVIDENCE-BASED BREAST REDUCTION TOPICS

This article is intended to highlight some steps used in breast reduction surgery that may be considered controversial.

Every patient is unique, so we cannot use the same surgical approach for every patient. The best technique is individualized to suit a patient's specific needs. There are many different factors that come into play when considering a breast reduction surgery, including the patient's skin, the position of their nipple-areolar complex (NAC), the volume and shape of their breasts, their age, and so on. Our expertise as surgeons is crucial when determining which method is the best for each patient.

PREDICTING COMPLICATIONS

There are many studies which show that a patient's baseline health status is an important predictor of complications in breast reduction surgery, but there is a great disparity in the results of each study. The use of the Clavien-Dindo classification¹ is therefore important because it allows a more objective comparison of the true incidence of complications.

BREAST IMAGING

Breast imaging is still quite controversial, especially in regard to patients under the age of 40. As a result, the cut-off age for breast imaging before surgery depends on the patients' location, background, and age. For patients under the age of 40, breast imaging may not always be possible, but for patients 50 or older, we should have an image control.²⁻³

INSURANCE COVERAGE

There are many different prediction scales, like the Schnur Sliding Scale from 1997, that are still used by insurance companies today to determine whether to cover a breast reduction surgery. There are two important aspects to consider about prediction scales:

1. There is no single scale that can accurately and universally predict the resection weight for all patients.
2. Often, insurance companies require a minimum of 750 g of tissue to be removed to provide coverage – however, symptom relief is not dependent upon the amount of tissue removed.

As a result, medical necessity should be based on the individual patient's symptoms and physical exam and on the physician's clinical judgment.

VASOCONSTRICTION INFILTRATION

Since we move and remove a lot of tissue during breast reduction surgery, blood loss is quite a concern. Using a tourniquet or epinephrine infiltration has resulted in the reduction of operative blood loss, independent of the concentration of epinephrine. Doing so does not increase the operative time of the procedure nor the chance of complications.⁴

DE-EPITHELIALIZATION

As a first-year resident, I was asked to perform the de-epithelialization technique to preserve the cutaneous microcirculation. However, the benefits of de-epithelialization are not yet sufficiently proven.⁵⁻⁶ At the moment, there is not enough evidence to determine whether this step is actually necessary.

BREAST PATHOLOGY

The prevalence of incidental atypical proliferative lesions in breast reduction surgery is 4-10%. Invasive lesions and DCIS lesions appear at a rate of 0.05-2.5%. Occult neoplasia may be associated with one's weight, age, and BMI.

Even though the use of preoperative imaging and histopathology protocols vary internationally, it is recommended to analyze patients above the age of 40 for any benign or malignant lesions, as well as patients below the age of 40 in cases where their BMI is >30 or where the weight of the resected breast is over 750 g.⁷

CONCLUSION

To summarize Dr. Hall-Findlay, the best breast reduction is the one that is performed the best by the surgeon. To that I would also add that the best breast reduction is the one in which the patient's desired outcome is met.

REFERENCES

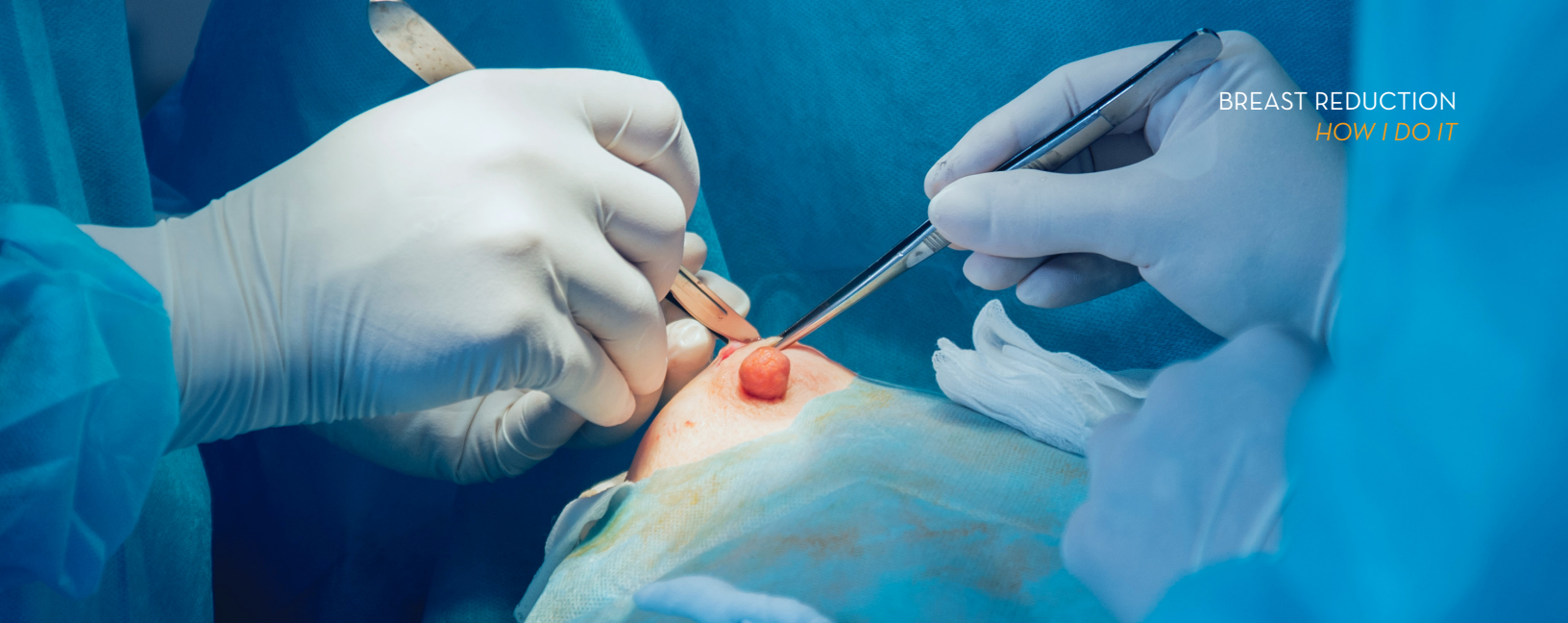1. Winter R, Haug I, Lebo P, Grohmann M, Reischies FMJ, Cambiaso-Daniel J, Tuca A, Riemüller T, Friedl H, Spindel S, Forbes AA, Wurzer P, Kamolz LP. Standardizing the complication rate after breast reduction using the Clavien-Dindo classification. *Surgery*. 2017 May;161(5):1430-1435.
2. Lowes S, MacNeill F, Martin L, O'Donoghue JM, Pennick MO, Redman A, Wilson R. Breast imaging for aesthetic surgery: British Society of Breast Radiology (BSBR), Association of Breast Surgery Great Britain & Ireland (ABS), British Association of Plastic Reconstructive and Aesthetic Surgeons (BAPRAS). *J Plast Reconstr Aesthet Surg*. 2018 Nov;71(11):1521-1531.
3. Sears ED, Lu YT, Swiatek PR, Chung TT, Kerr EA, Chung KC. Use of Preoperative Mammography During Evaluation for Nononcologic Breast Reduction Surgery. *JAMA Surg*. 2019 Apr 1;154(4):356-358.
4. Uslu, A. B. (2020). Effect of Tumescent Lidocaine and Epinephrine Infiltration on Blood Loss in Inferior

Pedicle Wise-Pattern Breast Reduction: A Prospective Randomized Study. *Aesthetic Plastic Surgery*, 1-9.


5. Ovadia, S. A., Bishop, E., Zoghbi, Y., Gasgarth, R., Kassira, W., & Thaller, S. R. (2018). Pedicle De-epithelialization in Reduction Mammoplasty: A Systematic Review of the Literature. *Aesthetic Plastic Surgery*, 42(1), 100-111.

6. Larsen, A., Hemmingsen, M. N., Ørholt, M., Andersen, P. S., Sarmady, F., Elberg, J. J., ... & Herly, M. (2020). Breast Reduction with Deskinning of a Superomedial Pedicle: A Retrospective Cohort Study. *Journal of Plastic, Reconstructive & Aesthetic Surgery*.


7. Sears, E. D., Lu, Y. T., Chung, T. T., Momoh, A. O., & Chung, K. C. (2019). Pathology Evaluation of Reduction Mammoplasty Specimens and Subsequent Diagnosis of Malignant Breast Disease: A Claims-Based Analysis. *World journal of surgery*, 43(6), 1546-1553.



JOSE ABEL DE LA PEÑA
MEXICO



GUILLERMO GALLARDO
MEXICO



PABLO RAMAZZINI
MEXICO

SCARLESS BREAST REDUCTION

USE OF ULTRASONIC LIPOSCULPTURE

Few procedures in our field have received as much attention and have stimulated the artistic capability of plastic surgeons as much as breast surgery has, in particular breast lift and breast reduction surgery. When performing these types of procedures, challenges include avoiding scarring, achieving fullness in the upper pole, preserving adequate vascularity and maintaining sensitivity in the nipple-areolar complex (NAC).

Despite the increased use of liposuction as a form of breast reduction surgery, few studies exist that examine the use of ultrasonic liposculpture alone in a breast reduction or a breast lift.

Leonardo da Vinci stated that shape, function and beauty must always work together. In line with this principle, skin viscoelastic properties are important in helping us determine which scar technique to use and how the breast's volume should be distributed. The goals are to lift the breast and reduce volume without leaving a scar.

Liposculpture can be done by placing a 2 cm long scar on the inframammary crease. I prefer to use ultrasonic liposculpture, as it facilitates the procedure by passing through the mammary gland and removing fat from the area. In addition, ultrasonic liposculpture lifts the breast and can elevate the NAC once

the breast's weight has decreased. Other benefits of this method include the achievement of breast symmetry, the potential for skin to have better viscoelastic properties, and a reduced risk of ptosis.

When evaluating a patient, surgeons must evaluate the patient's skin quality, breast volume, and NAC position. The ideal candidate will have no risk factors for breast disease or existing symptoms. A full-body exam, including a lab test and pregnancy test, is mandatory. For patients under the age of 39, a breast diagnostic ultrasound is indicated, and for patients over the age of 40, a mammography.

There is currently no scientific data on whether breastfeeding may be affected after undergoing ultrasonic liposculpture to the breast. However, in cases where the breast is mainly enlarged by fatty tissue, liposuction generally does not disrupt the glandular elements.

Prior to surgery, the patient should discontinue the use of any medications or substances that may impair coagulation. Markings are done to label the areas where liposuction will occur and the existence of any breast asymmetries. Peripheral zones are also marked to reduce the upper waist perimeter and to improve the shape of the new breast.

TECHNIQUE

Liposuction is performed using tumescent anesthesia and intravenous sedation. Immediately prior to surgery, prophylactic antibiotics are administered to the patient and the patient is positioned in the supine position. An incision is made in the inframammary crease for the tumescent infiltration. After

waiting for 15 minutes, ultrasonic liposuction begins, starting with the prepectoral fat. Next, the lateral and medial aspects of the gland are targeted. Here, care must be taken to preserve the fat for the upper pole of the breast, as the goal is to maintain fullness in the breast. Fat is then removed from the entire gland in order to sculpt breast volume and reduce the peripheral volume.

Depending on the technology used, fat may need to be evacuated. If so, it is important to record the amount of fat that has been evacuated. In addition, tissues may become loose and mobile. In this case, a contralateral procedure is done to achieve symmetry in both breasts.

Upon completion of the procedure, patients are given a post-op bra and sent to a hyperbaric chamber. Using a hyperbaric chamber post-operatively aids in the healing process, as liquid evacuates from the area and the chance of infection is reduced. Patients are told not to change their bra or wound dressing for the next five days. Over the next few months, the breasts will continue to reduce in volume and the skin will tighten (*Figures 1, 2*).

CONCLUSION

Ultrasonic liposculpture reduces the chance of injury to the thoracic wall, reduces bleeding, and results in firmer skin tightening. This technique is easy to perform by plastic surgeons who are familiar with liposuction and can improve quality of life for patients without the risk of producing visible scars. Additionally, among patients who have received this technique, there have not been any thermal nerve or glandular injuries.

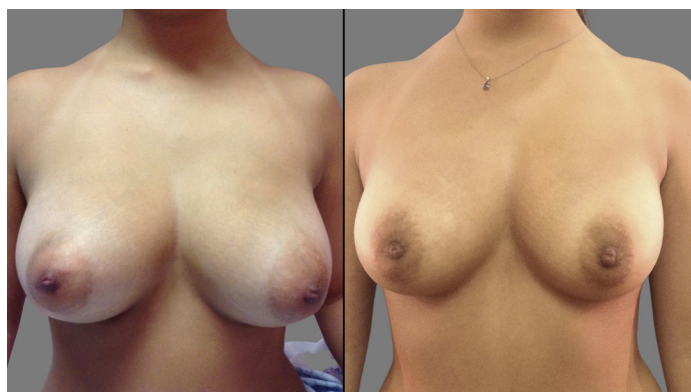


Figure 1: Side view of patient, pre-operation and 6-months post-operation.

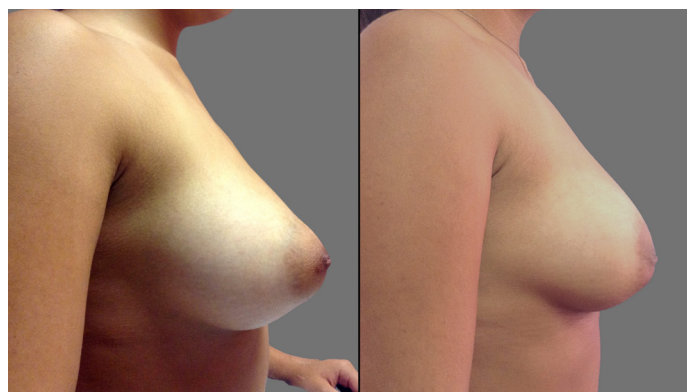

Figure 2: Front view of patient, pre-operation and 6-months post-operation.

BREAST REDUCTION



GUGLIELMO RUFFOLO
ITALY

INTRODUCTION

During this study I considered many different characteristics of patients. Often, patients suffer from body image dissatisfaction, which is one of the major factors that motivates patients to undergo a plastic surgery procedure. However, few studies have studied the association between body satisfaction and breast reduction.

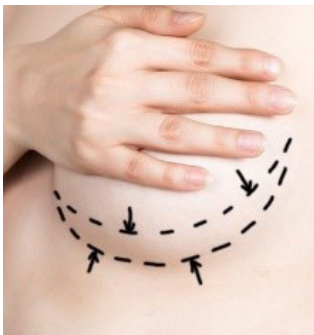

Figure 1.

OBJECTIVES

The goal of this study was to evaluate the impact of breast hypertrophy and breast reduction on body image (Figure 1).

METHODS

Breast hypertrophy patients, who had a mammoplasty reduction surgery already scheduled between June 2012 and December 2019 (mammoplasty group, MG), were prospectively evaluated using the body dysmorphic disorder examination (BDDE), body investment scale (BIS), and breast evaluation questionnaire (BEQ55) tools. Women with breasts of average size were also evaluated as study controls (normalized breast group, NSBG). In total, this study consisted of 50 women. All of the participants were interviewed at the initial assessment and after six months. I estimated a period of interview where data was analyzed before and after a period of six months. For a diagram illustrating the breast reduction surgery, please see Figure 2.

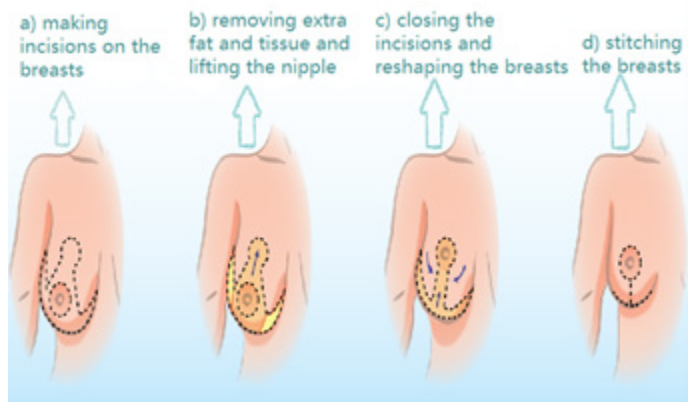


Figure 2: Step-by-step diagram of mammoplasty reduction surgery.

RESULTS

The MG group showed a significant improvement in their evaluation scores six months postoperatively, whereas the NSBG group showed no alteration in results over time. In the intergroup comparison, it was observed that the MG group began to have a more favorable body image, similar to that of the NSBG group. In fact, after surgery the MG group's level of satisfaction with their bodies surpassed that of the NSBG group.

CONCLUSIONS


Breast reduction procedures lead to an improvement in one's self-perceived body image among women including with breast hypertrophy. The final outcome for breast reduction patients was greater satisfaction in their appearance.

REFERENCES

1. Breast Reduction. Hall-Findlay EJ, Shestak KC. *Plast Reconstr Surg*. 2015 Oct;136(4):531E-544E.
2. Breast Hypertrophy, Reduction Mammoplasty, and Body Image. Fonseca CC, Veiga DF, Garcia EDS, Cabral IV, De Carvalho MM, De Brito MJA, Ferreira LM. *Aesthet Surg J*. 2018 Aug 16;38(9):972-979.
3. Breast Reduction in the Burned Breast. Powers KL, Phillips LG. *Clin Plast Surg*. 2016 Apr;43(2):425-8. DOI: 10.1016/J.CPS.2015.12.005.

COMBINING BREAST REDUCTIONS AND LIFTS

USING AN INFERIOR PARENCHYMAL FLAP FOR “AUTOLOGOUS AUGMENTATION”



RENATO SALTZ
UNITED STATES



FERNANDA SCALA
UNITED STATES

INTRODUCTION

Women may seek breast reduction surgery as a cosmetic or reconstructive procedure. Besides poor self-esteem, large breasts can also cause chronic back pain, skin irritation, and infections under the breasts.

When reducing the volume of tissue, women often prefer firmer, reshaped breasts with higher nipple-areolar complexes (NAC). To achieve this lifting effect, they are often advised to include a breast implant after the excision of redundant tissue. Alternatively, selected patients can undergo an “autologous augmentation mastopexy” procedure, where a part of their existing parenchyma can be projected into the upper pole and to the breast mound. This technique can reduce surgical costs and eliminate complications associated with breast implants. Even so, the potential for short-term recurrence of ptosis and the complexity of the procedures may not be appealing to some surgeons.

TIPS FOR A SUCCESSFUL AUTOLOGOUS AUGMENTATION MASTOPEXY

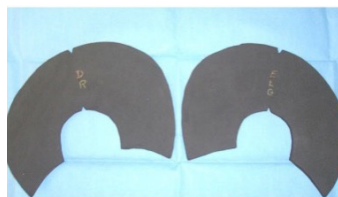

Figure 1: The Wise pattern as modified by Rezende.

Preoperative markings are based on a Wise Pattern that has been modified by Rezende¹ (Figure 1). By using templates, surgeons can save time and improve the final NAC symmetry. The dermolipoglandular inferior flap is designed with a 6-8 cm wide base and a height that varies according to the desired final projection of the breast. It can easily be tailored to achieve maximal symmetry in breast volume and projection.

Start the procedure by de-epithelializing the marked areas: the NAC pedicle and the inferior parenchymal flap. Parenchymal detachment from the pectoralis major muscle follows and is performed before undermining the superior NAC pedicle and sparing the de-epithelialized inferior flap, as described by Ribeiro². Care must be taken in the progression of parenchymal release from the pectoralis fascia to preserve the most superior segment once it will be the source of the NAC supply. The supply for the NAC is usually superior or superomedial, based on the length of the pedicle, the amount of tissue to be resected, and the distance from the sternal notch to the nipple.

The flap’s vascularization is provided by the fourth, fifth, and sixth intercostal perforating vessels of the internal mammary arteries. The axial vascularization allows easy cephalic repositioning of the flap at the chest wall and surgical fixation with sutures. The flap can be completely released from the inframammary fold (IMF) without compromising its vascularity, contributing to a tension-free and safe mobilization (Figure 2). The dermal release is done with a cautery, which also helps to tighten the skin at the IMF.

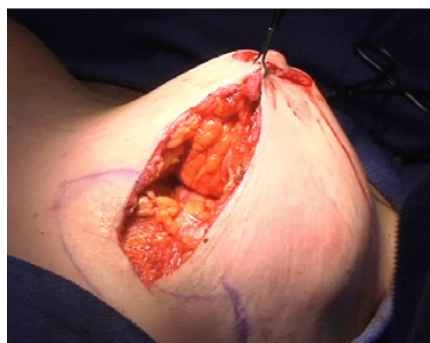

Figure 2: Intraoperative photograph shows the complete release of the dermolipoglandular inferior flap, allowing the flap to be placed in a more cephalic position secured by peripheral sutures.

Permanent sutures are placed around the entire inferior flap medially, laterally, and superiorly to embrace the dermis of the flap and the underlying muscular fascia. The dermal layer of the flap provides a strong structure to allow for long-term results. Sutures from the superior NAC pedicle are also extended to the top of the inferiorly based flap, bringing the two together. This also prevents the breast tissue from sliding over the inferiorly based flap, which can cause early relapse of ptosis.

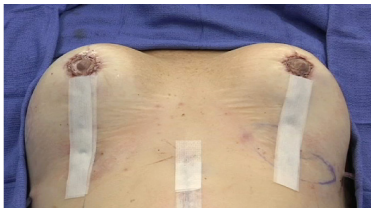


Figure 3: Demonstration of reduction of breast volume. Lateral and medial pillars are brought together over the dermolipoglandular inferior flap, while the IMF is raised for a full effect of an “autologous mastopexy.”

Reduction of breast volume usually takes place at the lateral pillars created after isolating the central flap (Figure 3), but may vary depending on which quadrant presents greater volume. The pillars are sutured centrally over the inferior pedicle. The final sutures must be

tension-free in order to avoid stretched scars or dehiscence. The NAC can also be excessively compressed by the inferior pedicle, which can lead to insufficient blood supply. In this case, sutures must be removed, and the additional tissue excised to avoid impairment to the venous outflow and subsequent necrosis.

Drains are placed around the top of the inferiorly based flap to eliminate any “dead space” and allow for early adhesion and healing. This could potentially be the main reason we do not see major changes in the overall shape and upper pole projection in long-term follow-ups.

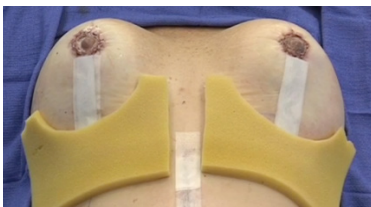

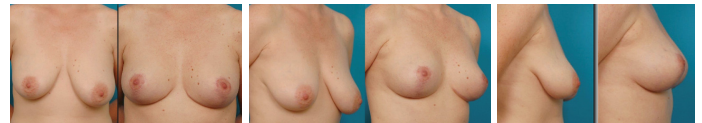
Figure 4: Postoperative dressing with foam compression to secure (fixate) the newly elevated inframammary folds.

Patients should wear a soft surgical bra with an additional foam mold positioned over the inframammary fold during the first two weeks post-operation (Figure 4). Doing

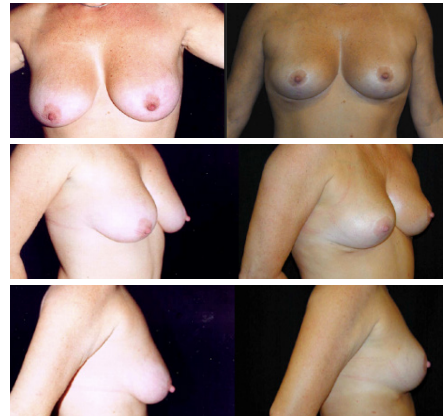so also stimulates skin adhesion in this area. Drains should be removed within 5-7 days and lymphatic drainage massage can be started as early as post-operative day four.

CONCLUSION

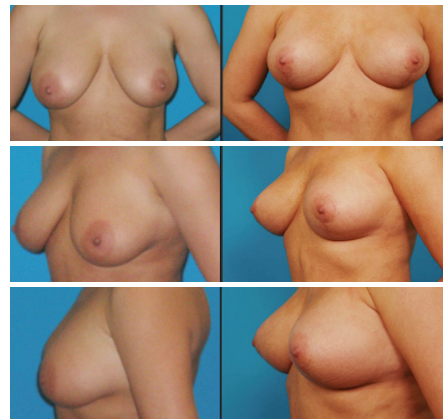With the autologous augmentation mastopexy technique, women can experience not only relief from macromastia symptoms, but also an improvement in their self-esteem as a result of firmer and better shaped breasts. It is a safe procedure that has a steep learning curve. In our experience, results are consistent for as long as 10 years of follow-up (Figures 5a-5i) and there is immense satisfaction from patients. A full description of the entire technique can be found in the beautiful, newly published *Atlas of Contemporary Aesthetic Breast Surgery* by Drs. Lee Pu and Mark Jewell.



Figures 5a, 5b, 5c: Preoperative and postoperative photographs of 1-year results.




Figures 5d, 5e, 5f: Preoperative and postoperative photographs of 8-year results.



Figures 5g, 5h, 5i: Preoperative and postoperative photographs of 10-year results.

REFERENCES

1. Rezende ARR, Rezende KL, Valente DS, et al. Molde de marcação pré-operatória em mamoplastia redutora: descrição de técnica operatória e avaliação de resultados. Rev. AMRIGS (Online). 2004; 43-s.
2. Ribeiro L, Accorsi A Jr, Buss A, Marcal-Pessoa M. Creation and evolution of 30 years of the inferior pedicle in reduction mammoplasties. Plast Reconstr Surg. 2002; 110(3): 960-70.
3. Saltz R & Scala F. Breast Lift with Inferior Parenchymal Flap in Atlas of Contemporary Aesthetic Breast Surgery by Pu & Jewell. Elsevier 2020.



OSCAR A. ZIMMAN
ARGENTINA

HOW TO TEACH BREAST REDUCTION SURGERY

WITH THE POSTERO-INFERIOR PEDICLE: A 3D MODEL

For a better understanding of how to perform breast reduction surgery using the postero-inferior pedicle technique, we created a “sponge” model to help young surgeons. The program was designed for residents during my tenure at the Hospital de Clínicas of the University of Buenos Aires, where I served as Chief of Division of Plastic Surgery from 2000 until 2014. The original description of this technique was first presented by Jalma Jurado¹ from Brazil, and then by Robbins², Courtiss and Goldwyn³, Kaplan⁴, and finally Jurado, who published his experience in 1979.

The postero-inferior pedicle technique has the following benefits:

- It is easy to teach and to perform
- If necessary, it is possible to check the weight of each quadrant and redo the excision at the same place (this is very important in cases of asymmetry)⁶

- In the case that a mistake is made and the pedicle is left too thin, a total vertical pedicle (mesentery) can be used, such as the McKissock technique⁷
- Each quadrant may be identified separately for pathology studies
- The cephalad end of the pedicle can be used to fill the upper pole

When using this technique, take the following precautions:

- Take care of the caudal portion of the septum and allow full visualization of the entire septal mesentery, so several perforating vessels in the septum can be seen. This technique optimally preserves the vascular and connective tissue support without excessive undermining of the pedicle⁸
- To avoid late ptosis, shorten the pedicle and fix it to the vertical incision

The postero-inferior pedicle technique is performed in the following steps:

1. Design of the technique (**Figure 1**)
2. Periareolar incision (**Figure 2**)
3. De-epithelialization of the vertical structure (**Figure 3**)
4. Resection of the lower medial quadrant (**Figure 4**)
5. Resection of the lower lateral quadrant
6. Examination of the septal mesentery (**Figure 5**) followed by resection of the upper pole, if the septal mesentery looks good enough to move forward (**Figure 6**)
7. Section of the medial and lateral pillars to connect the three quadrants (**Figure 7**)
8. Tailoring of the breast, including the size and shape
9. Placing of drains (**Figure 8**)
10. Plication of the inferior pedicle at the lower third using absorbable 3-0 sutures (**Figure 9**)
11. Placing of v-shaped sutures from the dermis to the pedicle (**Figures 10, 11**)
12. Placing of a skin suture (**Figure 12**)

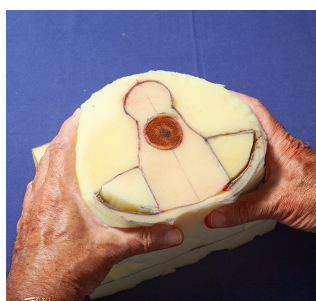

Figure 1: Design of the technique.



Figure 2: Periareolar incision.



Figure 3: De-epithelialization of the vertical pedicle.

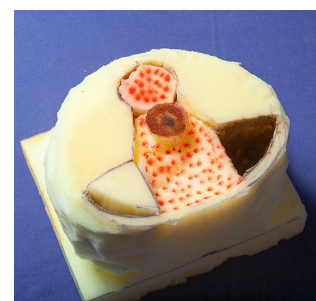

Figure 4: Resection of the lower medial quadrant.

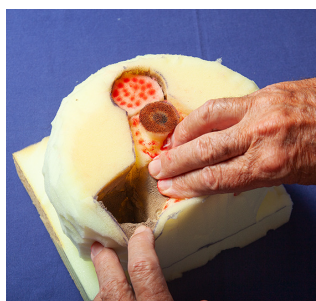


Figure 5: Examination of the septal mesentery.

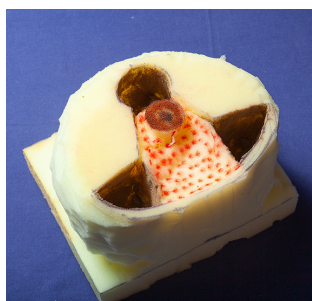

Figure 6: Resection of the upper pole.

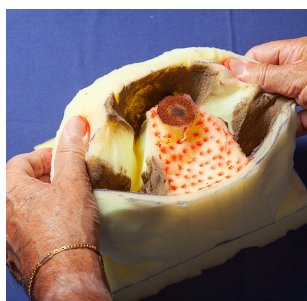

Figure 7: Section of the medial and lateral pillars.

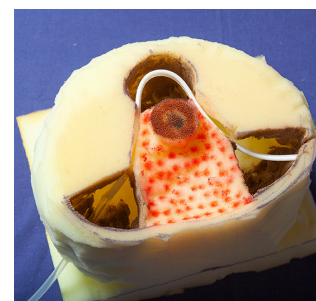



Figure 8: Placing of drains.

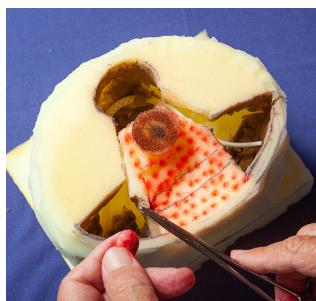

Figure 9: Plication of the inferior pedicle at the lower third.



Figures 10, 11: Placing of v-shaped sutures.

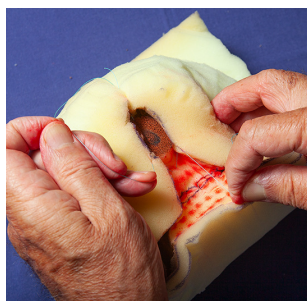


Figure 12: The final skin suture.


REFERENCES

1. Jurado, J. Breast Reduction based on a single vertical dermal pedicle (in Portuguese) *Annais 12º Congr.Brasileiro C.Plástica, Porto.Alegre, Brasil 1976*, pp29
2. Robbins, T.H. A reduction mammoplasty with areola-nipple based on an inferior dermal pedicle. *Plast.Reconstr.Surg.*, 59:64, 1977
3. Courtiss, E.H., Goldwyn, R.M. Reduction mammoplasty by the inferior pedicle technique. *Plast.Reconstr.Surg.*, 59:500,1977
4. Kaplan, I. Reduction Mammoplasty. Nipple-Areola survival on a single breast quadrant *Plast.Reconstr.Surg.*, 61:27,1978
5. Jurado, J. The vertical dermal-glandular flap of the inferior single pedicle in breast surgery. *Transactions 7th.International.Congress of Plastic and Reconstructive Surgery,IPRS, Rio de Janeiro 1979*.Ed.Cartgraf
6. Zimman O.A., Butto, C.D. Rostagno,R.,Rostagno,C. Volumetric Mammogram Assessment: A Helpful Tool in the Treatment of Breast Asymmetries. *Aesth.Plast.Surg.*41: 1261, 2017
7. McKissock,P.K. Reduction mammoplasty with a vertical dermal flap. *Plast.Reconstr.Surg.*,49:245, 2017
8. Hammond, D.C. *Atlas of Aesthetic Breast Surgery*. Saunders Elsevier, 2009

Microthane[®]

Micro-Polyurethane coated breast implants

Stability and dependability
when you need it most



POLYTECH Health & Aesthetics GmbH
Altheimer Str. 32 | 64807 Dieburg | Germany
www.polytechhealth.com

POLYTECH

PATIENT SAFETY

BREAST REDUCTION: PERSPECTIVES ON THE INFERIOR PEDICLE AND VERTICAL PEDICLE TECHNIQUES



JAMES FERNAU - UNITED STATES
ISAPS Patient Safety Committee



THOMAS FIALA - UNITED STATES
ISAPS Patient Safety Committee

DR. FIALA ON THE INFERIOR PEDICLE

Despite the increasing popularity of short-scar techniques for breast reduction, the Wise pattern reduction using an inferior pedicle remains popular in surveys among U.S. plastic surgeons.¹⁻³ This technique offers the following advantages: predictability of results, versatility of application, and control. Disadvantages include an increased scar burden, “bottoming out” or lengthening of the N-IMF distance with time, and wound healing issues, particularly at the T-junction point.¹⁻³

My personal technique begins with patient selection. Previous studies show that smoking, steroid use and high BMI are all linked to higher complication rates with this procedure.¹⁻³ Therefore, I do not offer this operation to active smokers (or those who frequently use e-cigarettes, vapes or marijuana). Former smokers must be fully smoke-free for two months. Steroid use is another contraindication. Our AAAASF-accredited facility is limited to ASA categories I and II, so patients with a BMI of >40 are not treated here. I strongly encourage pre-operative weight loss for patients with a BMI of >30.

Standard pre-op labs and EKG are obtained on patients over 40. I also obtain a pre-operative mammogram for women

over 40, assuming no additional risk factors for breast cancer, although this is controversial.^{2,3} The U.S. Preventive Services Task Force has recommended age 50 as their cutoff.

Other preparatory tips include pre-operative showers with antibacterial soap and chlorhexidine wipes to breast and axilla in pre-op holding area. Those with MRSA exposure history undergo a pre-op decolonization protocol.⁴ Multimodality analgesia is used: celecoxib, gabapentin, and acetaminophen are given orally in the pre-op area.⁵ Use of a comprehensive pre-op process checklist, as published by Rosenfield, is recommended.⁴

Marking is done in the pre-op holding area with a nurse chaperone. The patient midline, inframammary fold (IMF), and breast midline are marked as usual. The new nipple-areolar complex (NAC) location is estimated at or slightly above the Pitanguy point, but is not committed to until the T-closure has been completed in the operating room, and the patient has been checked in a near vertical sitting position. The inferior pedicle width is drawn with a wide base of 9-10 cm. I typically use a 42 mm NAC diameter. N-IMF limb length varies slightly with the desired size of the post-operative breast. For a medium C cup, it is set at 8-9 cm, which is slightly longer

than traditionally taught, to reduce tension. For women who desire a fuller C or small D size, this distance is lengthened, but does not exceed 10-11 cm. A small IMF triangle is also added to reduce tension at the T-incision. A gentle S-shape is used for the lateral flap design, to help avoid post-operative boxiness. I always check the limb lengths of the medial and lateral flaps, to make sure that the length of the flap is equal to, or slightly longer than, the corresponding distance along the IMF, and adjust marks as necessary.

Patients receive a single dose of IV Cefazolin within 60 minutes of incision.¹² Vancomycin is used in case of a penicillin allergy, or for those with suspected MRSA colonization. All patients are placed on a water-filled warming blanket for temperature maintenance. Sequential compression devices are used on all patients.² Patients with a Caprini score of >5 are considered for continued postoperative DVT prophylaxis.¹

The anesthesiologist routinely uses Propofol for induction and one of several inhaled agents for general anesthesia. Nitrous oxide is avoided. Ondansetron and dexamethasone are typically administered intravenously to reduce the risk of postoperative nausea and vomiting (PONV). Patients with a history of motion sickness or PONV receive aprepitant capsules prior to surgery. To reduce intra-operative bleeding, a single 10 mg/kg dose of tranexamic acid (TXA) is given about 30 minutes prior to incision.

I like to perform ultrasound-guided PECS I and II blocks following induction. It seems to help with patient comfort upon awakening and reduces the initial need for post-op pain medications.⁵

In surgery, while external skin incisions are made with a standard 15 blade, I use electrocautery for all parenchyma dissection. My preference is the Utah Medical "Epitome" electrosurgery tip, which cuts cleanly through dense breast tissue, while providing excellent hemostasis. All incisions are injected with an epinephrine-containing solution prior to initial incision.²

Following scissor de-epithelialization of the pedicle, the lateral and medial borders of the pedicle are created with a tapered edge. Care is taken to avoid undercutting the pedicle, especially on the lateral aspect. Medial and lateral triangles are resected. Less is taken medially to preserve desirable fullness. The resection specimens are preserved on the back table to compare to the opposite side. Flap elevation is performed, with thicker flaps to maximize flap perfusion. Dissection is performed slightly below the level of

the breast capsule inferiorly, and deepens as it goes superiorly, to help preserve some desirable superior pole fullness. The T-incision is temporarily tacked together, and the resection of the other side is completed. Thereafter, the patient is sat up and assessed for symmetry of shape. Any further zones requiring adjustment are dealt with at this time and resected tissue is sent for pathology examination.³

Finally, closure is performed. I prefer using 4-0 PDS for my deep dermal closure, placed about 1 cm apart. A Laschal pattern suture cutter helps the assistant avoid palpable suture tails. No drains are used.^{1,3} The NAC positions are drawn and checked carefully for symmetry. The skin disk is removed, and the NAC inset with 10-12 deep dermal sutures. A subcuticular suture is placed. Recently, I have been using the bidirectional 4-0 Monoderm barbed suture for the IMF, starting a few centimeters medial to the T-incision, and a second one for the periareolar and vertical closure. The T-incision is then covered with a mesh tape/cyanoacrylate dressing for two weeks, which is flexible, waterproof and antimicrobial.

Post-operative pain meds include celecoxib, gabapentin, and if needed, oxycodone/acetaminophen. Tapentadol is substituted for those with opioid sensitivities or with a PONV history. Early postoperative ambulation is encouraged.

Standard post-operative scar care includes the use of silicone gels during the day and silicone sheets at night over the incisions for the first three months. Patients with a history of hypertrophic scarring or those with a higher level of aesthetic concern are treated with the Embrace scar therapy system.^{6,7} Intralesional 5-fluorouracil combined with triamcinolone is used to minimize hypertrophic scars, if they are noted in the postoperative course.

DR. FERNAU ON THE VERTICAL PEDICLE

Dr. Fiala has provided an excellent comprehensive safety profile for inferior pedicle breast reduction. My technique differs in the following ways.

The decontamination protocol includes chlorhexidine showers and the application of mupirocin ointment to the ear canals, nostrils, NAC, and the umbilicus four times a day.⁸ The chlorhexidine showers and mupirocin ointment application are started five days before surgery. I use the enhanced recovery after surgery (ERAS) protocol.⁹ My use of general anesthesia also differs slightly. I do not use inhalation agents. The anesthesia team uses Propofol, dexmedetomidine, midazolam and a small amount of fentanyl on induction. I have modified the Rosenfield checklist to my practice.

A vertical pedicle is used with a lollipop incision. I use a superior or medial pedicle allowing for inferior wedge resection of the redundant ptotic breast tissue. Suturing the medial and lateral pillars results in coning of the breast. To accommodate for the increased projection, the new position of the superior border of the NAC is marked at the inframammary crease. Transposition of the NAC on a superior or medial dermal glandular pedicle depends on its position with respect to the mosque dome skin marking pattern. The breast parenchymal medial and lateral pillars are then closed with 0-Polyglactin (Vicryl-Sutures).

Gathering the skin of the vertical wound is accomplished by using boxed stitches with 3-0 polydioxanone (PDS) sutures. I infiltrate the lateral breast tissue located underneath the arm with a superwet solution of local anesthetic incorporating a

0.1% solution of TXA.^{10,11,12} I typically infiltrate 250-500 ml into the lateral breast, according to the size of the area of fullness. SAFE liposuction is performed with a power-assisted device using a 4 mm tri-port helix canula. No liposuction is performed medially. The breast parenchyma is infiltrated with 100-250 ml of this same solution. By using TXA, I avoid drains, bruising, hematomas, seromas, inflammation, and pain. Instead of using the Bovie cautery, I use a plasma knife. By doing so I have avoided seromas in over 500 patients.

In the post-operative period, the pro-fractional laser is used on scars when the redness diminishes and turns into a soft pink. This is usually 6-8 weeks post-operatively. I space the laser treatments at 4-6-week intervals and typically perform a minimum of six treatments for optimal scar reduction.

The authors have no financial interest in any company or product named in this article.

REFERENCES

1. Colohan SM, Massenburg BB, Gougoutas AJ. Breast Reduction: Surgical Techniques with an Emphasis on Evidence-Based Practice and Outcomes. *PRS*. 146, 339e-350e. 2020
2. Greco R, Noone B. Evidence-Based Medicine: Reduction Mammoplasty. *PRS* 139: 230e-239e. 2017.
3. Kerrigan CL, Slezak SS. Evidence-Based Medicine: Reduction Mammoplasty. *PRS* 132: 1670-1683, 2013.
4. Rosenfield, L. Operating Room Checklist. Downloaded from: <https://www.surgery.org/downloads/scissors-on-the-seam/OperatingRoomChecklist.pdf>
5. Murphy AM, Haykal S, Lalonde, DH, Zhong T. Contemporary Approaches to Postoperative Pain Management. *PRS* 144(6) 1080e-1094e, 2019.
6. Khansa I, Harrison B, Janis JE. Evidence-Based Scar Management: How to Improve Results with Technique and Technology. *PRS* 138: 165S-178S
7. Perez JL, Rohrich RJ. Optimizing Postsurgical Scars: A Systematic Review on Best Practices in Preventative Scar Management. *PRS* 140, 782e-793e, 2017.
8. Fernau, J. Recommended Preoperative Decolonization Protocol. International Society of Aesthetic Plastic Surgery. Patient safety recommendations. Issue Date 20 December 2016
9. Fernau, J. The ERAS Protocol for Improving Patient Safety. *Aesthetic Society News*. Vol 23, Number 1; 84-87. Winter 2019.
10. Fernau, J. Is it Time To Use Tranexamic Acid to Enhance Patient Safety? *Aesthetic Society News*. Vol 23, Number 2; 128-29. Spring 2019.
11. Fernau, J. The Use of Tranexamic Acid for Patient Safety. *ISAPS News*. January-March 2019 Vol 13 (1) 32-33.
12. Fernau, J. Patient Safety in Rhinoplasty and Tranexamic Acid Protocols. *Aesthetic Society News*. Vol 25, Number 1; 62-66. Winter 2021.

PATIENT SAFETY

FAT NECROSIS IN BREAST SURGERIES: HIGHER INCIDENCE IN FIBROCYSTIC DISEASE (FCD) OF THE BREAST



ROY KANJOOR
INDIA

INTRODUCTION

Fat necrosis (FN) in the breast following a breast surgery is a benign but confusing complication that needs thorough investigation to rule out malignancy. The true incidence is difficult to report. After fat grafting to the breast, the reported incidence of FN is between 2-20%.¹ Fat grafting to the breast is a different type of breast surgery in which fat cells or tissue are grafted into the breast. This is mainly done with subcutaneous fat. FN has also been reported in other surgeries involving breast tissue including breast reductions, breast implant surgeries, and breast biopsies.

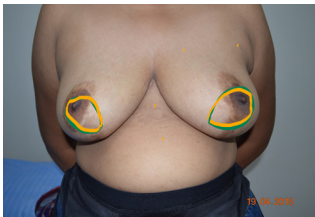

Figure 1a: Patient had undergone a large breast reduction two years earlier and now presented with a hard-palpable mass under the NAC. It was a long superomedial pedicle. A small incisional biopsy found FN and FCD.

of fat necrosis, there was good viability and sensation of the nipple-areolar complex (Figures 1a, 1b).

PATHOLOGY

The likely pathogenesis of fat necrosis is ischemia. When the tissue load is overwhelmed, fat cells are the first to undergo necrosis whereas the nerves can withstand hypoxia to a larger extent. This was observed when we performed large breast reductions using long pedicles. Though we observed firm to hard pedicle, which is indicative

The pathologic stages of retained necrotic fat lead to continued fibrosis and calcification. As necrotic fat continues to mature, it becomes fixed to the surrounding tissues.

The following types of fat necrosis were observed on patients where fat had been grafted to the breast:¹

1. Fat oil cyst
2. Calcification
3. Nodular sclerosis
4. Large lumps

CLINICAL FEATURES

In our experience, we observed that hard, lumpy presentation occurred after breast reduction surgery while oil cysts occurred after fat grafting. Common symptoms among patients included pain around the breasts and visible lumps. These effects usually presented themselves anywhere from three weeks to one year after surgery.

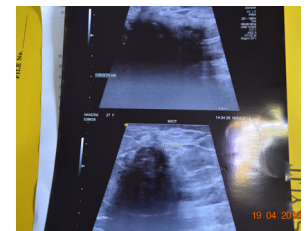


Figure 1b: Ultrasound image showing a hard mass under the NAC.

MANAGEMENT

The protocol for determining whether fat necrosis is benign or malignant involves investigating whether there are visible lumps and pain in the breast area. An ultrasonogram or mammogram may be used to determine if there are calcified walls or cysts present and if there are any opaque areas present, which are indicative of hard areas (**Figures 2a, 2b, 2c**).

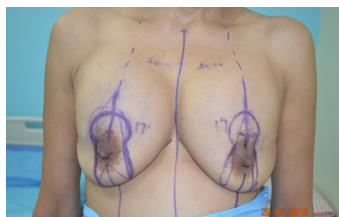


Figure 2a: Patient who underwent implant removal and mastopexy for a waterfall deformity as well as concomitant fat grafting.

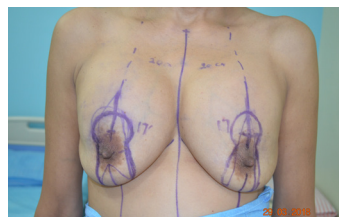


Figure 2b: Patient presented with a clearly defined mass eight months later.

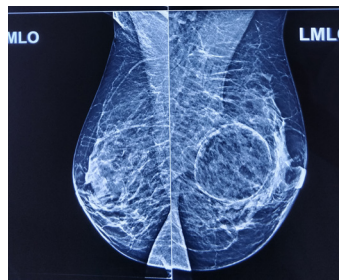
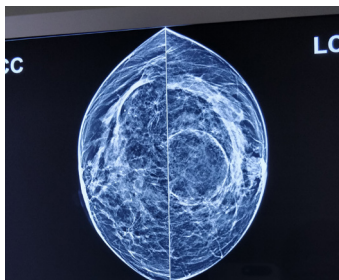


Figure 2c: Ultrasonogram images of a large oil cyst which was biopsied and showed both FN and FCD.

If the patient reports no pain or lumps in the breast, no investigation is done. Pain associated with lumps requires removal of the cyst (**Figures 3a, 3b**). Small cysts can be removed by fine-needle aspiration.

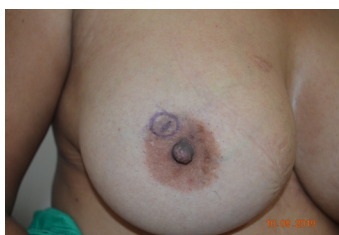

Figure 3a: 40-year-old female who had breast implant surgery five years ago and fat grafting to the breast two years ago. She developed a painful small nodule.

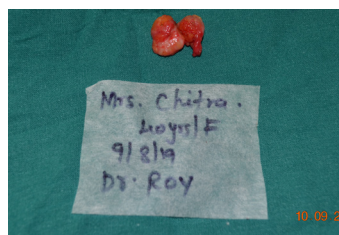


Figure 3b: Excisional biopsy showed a fat oil cyst and FCD.

OUR EXPERIENCE

Our observation of the coexistence of fibrocystic disease (FCD) and fat necrosis caused us to look back and explore all cases of FN that we had found. There were two large breast reductions and four fat grafting procedures where there was FCD of the breast in the clinical history and histopathological evidence of FN and FCD coexisting.

Upon discovering this, we asked patients about any potential premenstrual pain or breast enlargements, which are common symptoms of FCD. We then performed soft tissue mammograms and ultrasound exams after which we alerted patients of any presence of FCD (BI-RADS 2). We also warned patients of the likely occurrence of a lumpy breast post-surgery, whether from a breast reduction surgery, fat graft, or breast implant surgery.

DISCUSSION

FCD is a benign breast disease. There is a link between breast reduction surgery, proliferative breast disease and a reported increase in complications postoperatively.²

Indicators that were predictive of specific complications post-breast reduction surgery included a patient's body mass index (BMI), race, and mass of resection.³ Complications that may occur post-operatively include complications with the healing of a wound, decreased nipple sensitivity and hypertrophic scarring.³

Though the association between fibrotic or proliferative breast tissue and higher incidence of overall complications has been reported, this association has not been studied in relation to any single specific complication. Our research on this novel link between FCD and FN has not been reported previously in the literature. However, the association between FN and FCD can help us predict the chance of developing the disease and allow us to warn patients beforehand. Preoperative screening of the breast using BI-RADS can help us document any presence of FCD.

CONCLUSION

The rare association between fat necrosis and fibrocystic disease of the breast can help plastic surgeons better counsel patients about the likely complication of fat necrosis and its effects.

REFERENCES

1. Lin JY, Song P, Pu LLQ. Management of Fat Necrosis after Autologous Fat Transplantation for Breast Augmentation. *Plast Reconstr Surg*. 2018 Nov;142(5):665e-673e. doi: 10.1097/PRS.0000000000004898.
2. Henry, Steven L.; Crawford, J Lauren; Puckett, Charles L. Risk Factors and Complications in Reduction Mammoplasty: Novel Associations and Preoperative Assessment. *Plast Reconstr Surg*. 2009;124(4):1040-1046.
3. Sommer NZ, Zook EG, Verhulst SJ. The prediction of breast reduction weight. *Plast Reconstr Surg*. 2002;109:506-511.

ISAPS Welcomes New Members

November 2020 - January 2021

You can find all degrees of the new members in the membership directory at: <https://www.isaps.org/member-directory>

ALBANIA

Ina Kola

ARGENTINA

Luis Maria Mastronardi
Guillermina Patricia Montion
Juan Esteban Martinez
Luciana Flores Bassino
Maria Guillermina Cei

AUSTRALIA

Lisa Jane Friederich

AUSTRIA

Ingo Plötzeneder

BELARUS

Berat Oyur

BELGIUM

Jean-Valéry Berthe
Bernd Lannau

BRAZIL

Arthur Koerich D Avila
Giovanni Bezerra Martins
Marcelus Vinicius Nigro Sr.
Debora Cristiam Galvão
Jose Luis Araujo Pastor
Ana Alice De Carli De Azevedo
Flavia Bonato
Newton Thomaz Correa Filho
Rafael De Fina
Renato Perali
Rodrigo De Gouveia Franco
Rodrigo Sousa Nascimento
Rosa Maria Marquezini Cara
Wagner Allan Bertolotte
André Granieri De Oliveira Araujo
Galo Andres Verdugo

BULGARIA

Ruslan Tachev

COLOMBIA

John Jairo Valencia Quintero Sr.
Daniel Camilo Rivera Muñoz

FRANCE

Claude Le Louarn
Frederic Germain
Johan Luce
Massimo Gianfermi
Frédérique Bellier-Waast
Olivier Claude

GEORGIA

Giorgi Mamardashvili
Mariam Tsvitsivadze

GERMANY

Andreas Moeller
Veronika Mandlik
Anna Lukyanova
Andreas Moeller
Mehrnoosh Akhavanpoor
Nima Ahmadzadeh
Saleh Mohammed Alhotan
Constantin Carlos Weil Von Der Ahe

GREECE

Panagis Nikolaos Georgiou
Anastasios Pagkalos
Vasiliki Bostani

HUNGARY

Zsófia József

INDIA

Shivani Atri Singh
Krishna Prasad Shetty

IRAN

Ali Alavirad

IRAQ

Waleed Ali Totonchi Sr.
Jabir Hameed

ISRAEL

Sarit Cohen
Or Friedman
Roy Teman
Yossi Namir

ITALY

Andrea Di Leo Sr.
Piero Crabai

KAZAKHSTAN

Yerlan Tulebayev

LATVIA

Marta Taurite

LEBANON

Natasha Toni Habr

LITHUANIA

Jonas Drasutis

MEXICO

Alexandro Fernando Aguilera Salgado
Denisse Hernandez
Aldo Antonio Perez Colin Sr.
Bertha Estefania Garcia Ramirez
Guillermo J Gallardo
Hector Ortiz-Martinez
Jorge Arturo Rojas Ortiz
Luis Francisco Montano Nataniel Ii
Marco Aurelio Rendon Rendón-Medina
Maria De Los Angeles Mendoza Velez Iii
Rodrigo Otero
Ruth Marcel Arias Morillo
Jose Carlos Martinez Lopez
Ricardo Emmanuel Zaragoza Carrillo

MOLDOVA

Mariana Cupcea
Angelica Gutu

MOROCCO

Salaheddine Slaoui

NETHERLANDS

Julia Zguricas
Gertjan Halbesma

NORTH MACEDONIA

Ana Rajkovska Kimovska

PERU

Jorge Luis Marcos Quispe

POLAND

Marta Malgorzata Wilczynska-Staniul
Fryderyk Menzel

PORTUGAL

João Morais

ROMANIA

Daniel Popescu
Mordechai Yair Levy
Cristina Elena Berbecar-Zeca
Anca Emilia Oprescu
Daniela Elena Gheoca Mutu

RUSSIA

Alexander Mikhaylov
Irina Sarkisyan
Natalya Zelenkova

SAUDI ARABIA

Hatem Alnoman
Abdullah Bahi

SERBIA

Dusan Pravica

SINGAPORE

Michael Hsieh

SLOVENIA

Katarina Zivec

SPAIN

Emma Torres
Ignacio Laloumet Martín Sr.
Marco Ranieri
Alejandro Fernandez-Quinto

SWEDEN

Dhafir Dawood Hanoon

SWITZERLAND

Stéphane Smarrito
Mickaël Tobalem

THAILAND

Tanasit Kangkorn

TURKEY

Cagdas Orman
Fazli Cengiz Bayram
Hakan Agir
Arda Ozdemir
Dinçer Akkus
Etkin Boynuyogun
Fatih Cinar Iv
Mehmet Solmaz
Necip Sefa Özden
Onur Aksoy
Ugur Kaan Kalem

UKRAINE

Oleksandr Borota Jr.

UNITED KINGDOM

Hazem Alfie
Parkash Lohana
Zahid Hassan
David Izadi
Riaz Agha

UNITED STATES

Kaveh Alizadeh
Shawn Birchenough
Joseph Khouri
Minh-Doan Thi Nguyen
Mune Gowda
Rosendo Emilio Martinez
Shahin Fazilat
Casey Kraft
David Parizh
Diana Carrau
Marco Swanson
Philipp Franck

VENEZUELA

Manuel Jose Lazzaro Estevez

ISAPS®

THANK YOU
TO OUR
**ISAPS GLOBAL
SPONSORS**

**ISAPS GLOBAL SPONSOR
PLATINUM**

PLATINUM Sponsor:

MENTOR®
PART OF THE *Johnson-Johnson* FAMILY OF COMPANIES

POLYTECH

**ISAPS GLOBAL SPONSOR
GOLD**

GOLD Sponsor:

Bio | SCIENCE

GC Aesthetics™



The Art of Science

GCA's novel Round Breast Implant with (R)evolutionary BioQ™–Surface technology and highly cohesive Emunomic™ Breast Tissue Dynamic Gel.

Crafted with 40 years of experience and backed by our reputation for long-term safety.¹

Discover PERLE:™
www.gcaesthetics.com

AVAILABLE IN LIMITED MARKETS



Covered by:



1. Duteille F, et al. Aesthet Surg J Open Forum 2019;1(2): 1–10.

MEETINGS CALENDAR



Master Class Webinar Series 2021
Topics: Monthly topics in Aesthetic Plastic Surgery
Link to register:
www.isaps.org/master-class-webinar-series-2021

RESIDENT WEBINAR: BASICS IN BODY CONTOURING – ABDOMINOPLASTY

Date: March 13, 2021
Speakers: Dr. Maria Wiedner & Dr. André Cervantes
Moderator: Dr. Gustavo Abrile
[Click here](#) to register! FREE FOR ISAPS RESIDENT MEMBERS!
Free for ISAPS resident members; \$50 for Active/Associate members. Please note this is a member only event.

55TH BAKER GORDON EDUCATIONAL SYMPOSIUM – ISAPS ENDORSED NEW DATE

Date: March 18 – 20, 2021
Location: Miami, FL, USA
Venue: Hyatt Regency Hotel
Contact: Mary Felpeto
Telephone: 1-305-854-8828
Fax: 1-305-854-3425
Email: maryfelpeto@bellsouth.net
Website: www.bakergordonsymposium.com

ISAPS WORLD – VIRTUAL EVENT

Date: March 27 – 28, 2021
Website: www.isapsworld.com

Our ISAPS WORLD program will follow the sun, featuring a non-stop program, wherever you are: Australia, New Zealand & Far East Asia, Middle East, Africa & India, Europe, North & Latin America.

ISAPS COURSE – GREECE COURSE POSTPONED UNTIL JULY 8-10, 2021

Dates: April 1-3, 2021
Location: Athens, Greece
Venue: Radisson Blu Park Hotel
Contact person: Vicky Delidimitriou, vdelidimitriou@noufio.gr
Tel: +30 210 - 2775219
Fax: +30 210 - 2714437
Website: www.isapscourseathens2020.gr
Organizing Secretariat: NOUFIO www.noufio.gr

ISAPS WEBINAR – ISAPS BUSINESS SCHOOL

Date: April 17, 2021
Speakers: TBD
Moderator: Renato Saltz

ISAPS MASTER CLASS WEBINAR – ASIAN RHINOPLASTY

Date: April 24, 2021
Time: 13:00 UTC – 15:00 UTC
Speakers: Eun Son Dhong & Man Koon Suh
Moderator: Nazim Cerkes
Link to register:
www.isaps.org/master-class-webinar-series-2021

BARCELONA RHINOPLASTY 2ND COURSE – ISAPS ENDORSED

Date: April 28 – May 1, 2021
Location: Barcelona, SPAIN
Venue: Centro Medico Teknon
Contact: Silvia Vila
Tel: 34 9 33933 128
Email: svila@vilarovira.com
Website: www.barcelonarhinoplasty.com

ISAPS HAIR TRANSPLANTATION COURSE

Date: May 8 - 9, 2021
Location: Istanbul, Turkey & Virtual
Contact: Seven Event Company
Email: hello@seveneventcompany.com
Website: www.isapshairtransplantationcourse.org/Default.asp

ISAPS SYMPOSIUM – CHILE

Dates: May 13, 2021
Location: Santiago, CHILE
Venue: Hotel Plaza El Bosque Nueva Las Condes
Contact: Dr. Montserrat Fontbona
Tel: +56-226-320-714
Email: soccpchile@gmail.com
Website: www.sccp.cl

ISAPS MASTER CLASS WEBINAR – MALE BODY CONTOURING

Date: May 15, 2021
Time: 13:00 UTC – 15:00 UTC
Speakers: Henry Mentz & Kai Schlaudraff
Moderator: Cemal Tg Senyuva
Link to register:
www.isaps.org/master-class-webinar-series-2021

ISAPS REGENERATIVE MEDICINE VIRTUAL SYMPOSIUM

Date: May 29, 2021
Speakers: TBD
Moderator: Katarina Andjelkov, Renato Saltz & Reha Yavuzer

15TH INTERNATIONAL FRESH CADAVER COURSE ON FACELIFT AND PERI-ORBITAL PROCEDURES – ISAPS ENDORSED

Dates: June 4-5, 2021
Location: Utrecht, NETHERLANDS
Venue: Medical University
Contact: Jacques van der Meulen
Tel: +31 641 461 496
Email: drvdMeulen@gmail.com
Website: www.drtulp.nl

33RD ANNUAL CONGRESS OF SOFCEP – ISAPS ENDORSED

Dates: June 10-12, 2021
Location: Les Sables d'Olonne, FRANCE
Venue: Centre de Congres des Atlantes
Contact: SOFCEP
Tel: +33(0)53 431 0134
Email: sofcep@vous-et-nous.com
Website: www.chirurgiens-esthetiques-plasticiens.com/congres-sofcep-2/?lang=en

EURASIAN AESTHETIC SURGERY-ISAPS COURSE

Dates: June 17-19, 2021
Location: Istanbul, TURKEY
Venue: Hilton Istanbul Convention & Exhibition Center
Contact: Seven Event Company
Tel: +90 212 216 0013
Email: hello@seveneventcompany.com
Website: www.eurasian2021.org

ISAPS ENDORSED – 8TH LIVE SURGERY COURSE

Dates: June 24 – 26, 2021
Location: Marbella, SPAIN
Venue: Hotel Barcelo Marbella
Contact: Carolina Lerussi
Tel: +34 952 77 53 46

Email: carolina@cirumed.es
Website: livesurgery.cirumed.es

WEBINAR – USE OF SURGICAL NET IN FACIAL AESTHETIC SURGERY

Date: June 26, 2021
Time: 13:00 UTC – 15:00 UTC
Topic: Use Of Surgical Net in Facial Aesthetic Surgery
Speakers: Fausto Viterbo, MD, PhD & Andre Auersvald, MD
Moderator: Ozan Sozer, MD

SECONDARY OPTIMIZING AESTHETIC SURGERY SYMPOSIUM (SOS) 2021 – ISAPS ENDORSED

Dates: September 7-8, 2021
Location: Vienna, AUSTRIA
Venue: Andaz Belvedere Vienna Hotel
Contact: Barbara Boeld
Tel: +49-89-18-90460
Email: Congress@bb-mc.com
Website: www.sos2020.eu

ISAPS COURSE – HUNGARY

Dates: November 4-6, 2021
Location: Debrecen, HUNGARY
Venue: Kölcsey Convention Center Debrecen
Contact: Dr. Csaba Molnár
Tel: (+36 1) 299 0184
Email: convention@convention.hu
Website: www.isaps-debrecen2020.hu



ISAPS[®] WORLD
The sun never sets on ISAPS.

ISAPS VIRTUAL EVENT - MARCH 27-28, 2021
www.isapsworld.com



www.isapsvienna2021.com

ISAPS[®]
WORLD CONGRESS

NEW DATES!

50th
ANNIVERSARY

SEPTEMBER 9 – 12, 2021 | VIENNA, AUSTRIA

ISAPS EXECUTIVE OFFICE STAFF

10 Benning Street, Suite 160 #264
West Lebanon, NH 03784-3402
United States
Phone: 1-603-643-2325
Email: ISAPS@isaps.org
Website: www.isaps.org

EXECUTIVE DIRECTOR

Sarah Johnson

FINANCE OFFICER

Sean Finnell

ASSOCIATE DIRECTOR OF US OPERATIONS

Michele Nilsson, CMP (USA)

MEMBERSHIP MANAGER

Richard Guy (UK)

EXECUTIVE ASSISTANT & OPERATIONS MANAGER

Stephanie Halksworth (UK)

DIGITAL PROJECT MANAGER

Laura Lundy (UK)

ISAPS NEWS MANAGEMENT

EDITOR-IN-CHIEF

Arturo Ramirez Montañana, MD (Mexico)

CO-CHAIR, ISAPS NEWS

Fabian Cortiñas, MD (Argentina)

MANAGING EDITOR

Cheyenne Ziermann (Germany)

GRAPHIC DESIGNER

Doris Pfifferling (Germany)

EMERITUS EDITORS

J. Peter Rubin, MD, FACS (United States)

Nina Naidu, MD (United States)

EMERITUS MANAGING EDITOR

Catherine Foss (United States)

Board of Directors

President
President-Elect
Secretary
Treasurer
Membership Chair
Member-at-Large
Member-at-Large
Member-at-Large
Member-at-Large
Past President
National Secretaries Chair
Parliamentarian
Education Council Chair
Education Council Vice Chair
Trustee
Executive Director

Nazim Cerkes, Turkey
Lina Triana, Colombia
Arturo Ramirez-Montañana, Mexico
Tim Papadopoulos, Australia
Vakis Kontoes, Greece
Fabian Cortiñas, Argentina
Kai-Uwe Schlaudraff, Switzerland
Ivar van Heijningen, Belgium
Niveo Steffen, Brazil
Dirk Richter, Germany
Michel Rouif, France
Sanguan Kunaporn, Thailand
Ozan Sozer, USA
Francisco Bravo, Spain
Renato Saltz, USA
Sarah Johnson, UK

Standing Committee Chairs

Executive
Nominating
Membership
By-Laws
Communications
Patient Safety
Journal Operations
Finance, Investment and
Industry Relations
Newsletter

Nazim Cerkes, Turkey
Dirk Richter, Germany
Vakis Kontoes, Greece
Renato Saltz, USA
Fabian Cortiñas, Argentina
Niveo Steffen, Brazil
Lina Triana, Colombia

Kai Schlaudraff, Switzerland
Fabian Cortiñas (Argentina) &
Arturo Ramirez-Montañana (Mexico)
Maria Wiedner, Germany
Lina Triana, Colombia

Ivar van Heijningen, Belgium
Dirk Richter, Germany

Residents
Women Plastic Surgeons
Corporate Governance
and Policy
Technology/IT

Education Council

Chair
Co-Chair

Ozan Sozer, USA
Francisco Bravo, Spain

Ad Hoc Committee Chairs

Humanitarian
Insurance
Website
Global Survey
IBOPRAS
Global Accreditation
Visiting Professor
Global Alliance
Patient Education
Webinar/E-Learning
Social Media
ISAPS Fellowship Program

Tunc Tiryaki, Turkey
Kai Schlaudraff, Switzerland
Lina Triana, Colombia
Arturo Ramirez-Montañana, Mexico
Ivar van Heijningen, Belgium
Ozan Sozer, USA
Renato Saltz, USA
Nazim Cerkes, Turkey
Stefano Danilla, Chile
Ozan Sozer, USA & Francisco Bravo, Spain
Fabian Cortiñas, Argentina
Maria Wiedner, Germany

DISCLAIMER:

ISAPS News is not responsible for facts, opinions, and other information presented by the authors or advertisers in this newsletter or otherwise. This newsletter presents current scientific information and opinions pertinent to medical professionals. It does not provide advice concerning specific diagnosis and treatment of individual cases and is not intended for use by the layperson. Readers are strongly advised to confirm that the facts, opinions, and other information comply with the latest legislation and standards of practice. ISAPS, the editors, the authors, and the publisher will not be responsible for any errors or liable for actions taken as a result of facts, opinions, and other information expressed in this newsletter or otherwise. Copyright © 2021 by the International Society of Aesthetic Plastic Surgery, Inc. All rights reserved. Contents may not be reproduced in whole or in part without written permission of ISAPS.



ISAPS[®] WORLD

The sun never sets on ISAPS.

MARCH 27-28, 2021

We are excited to bring you ISAPS WORLD: our world-first non-stop 48-hour aesthetic conference coming to you in two weeks! This unique virtual event will feature more than 400 speakers in five different regions: Australia, New Zealand & Far East Asia; the Middle East, Africa & South Asia; Europe; North America and Latin America. **Discover our faculty** to see some of the highlights from each region!

Our fully virtual program will feature a state-of-the-art scientific program with expert panels, hot topics, and a live virtual exhibition, as well as live translations for the following regions:

- Asia: simultaneous translation into Mandarin
- Middle East, Africa & South Asia: French and English subtitles
- Europe: simultaneous translation into Russian
- Latin America: Spanish, Portuguese and English subtitles

Registration starts at only \$100*, so **register now** for ISAPS WORLD and tune in this March 27-28 from your home, your office, or wherever you are! Unable to join us for one of our regional sessions? The entire program will be available On Demand for delegates for up to one month after the event, so you can catch up on any speakers you may have missed.

*ISAPS member rate, ISAPS resident members register for just \$25

